DUYGULARIN ANATOMİSİ

Prof.Dr.Nazan Aydın

Phineas Gage

Kazadan önce

Verimli ve becerikli
dengeli bir zihin
enerjik, kararlı, ılımlı

Düzensiz, düşüncesiz,
eskiden kullanmadığı en kaba küfürlere düşkün,
sınırlara ve öğütlere tahammülü olmayan,
inatçı, kaprisli,kararsız, planlar kurup hemen vazgeçen
çabuk öfkelenen biri

Kazadan sonra

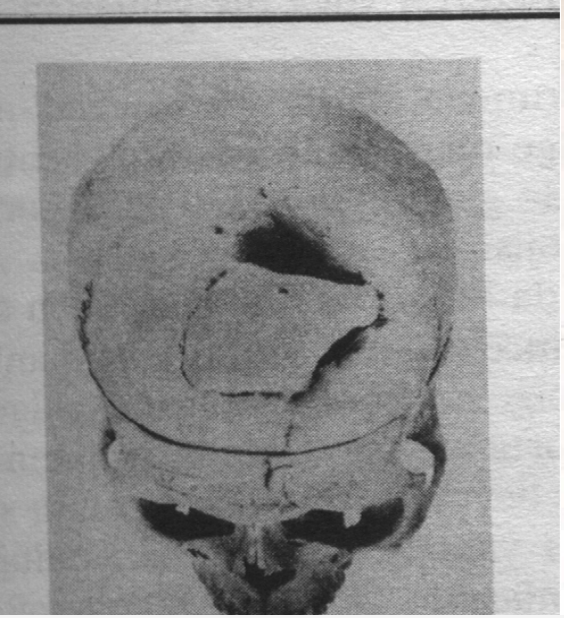

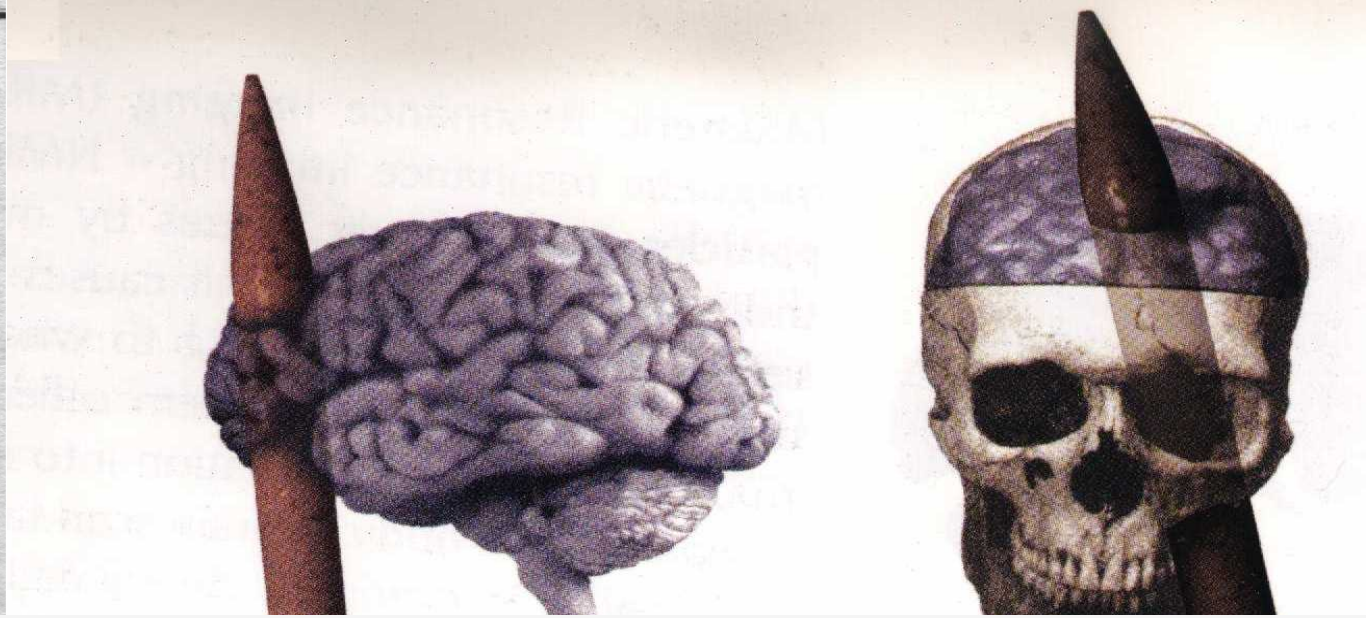

Harlow, J.M. (1848). "Passage of an iron rod through the head".
Boston Medical and Surgical Journal 39: 389-393. (Republished in *Journal of Neuropsychiatry and Clinical Neuroscience* 11, 281-283; and in Macmillan 2000)

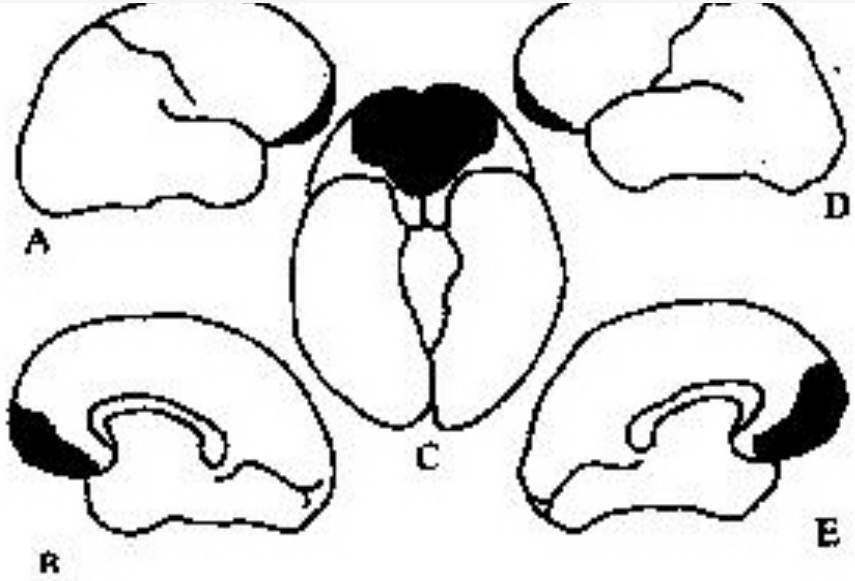

• Elliot

Yüksek zeka
Algılama yeteneği, bellek,
dil ve aritmetik işlem yeteneği
normal

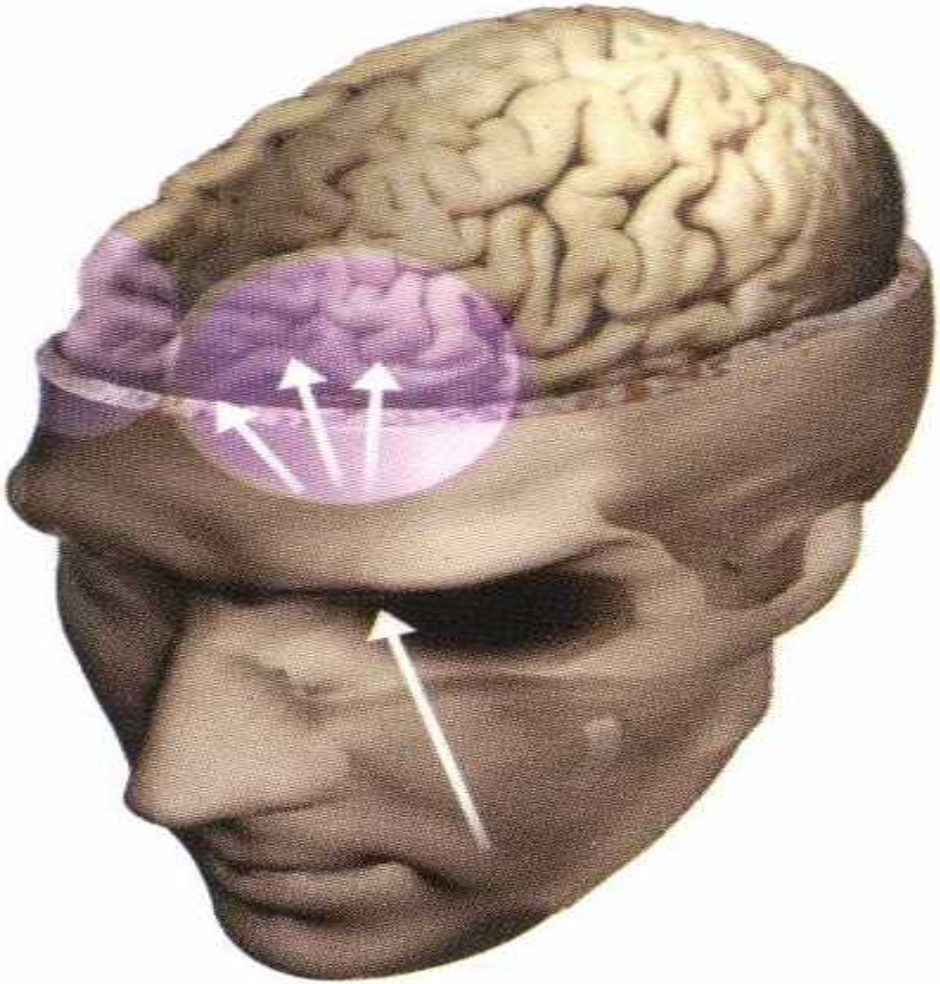

Karar verememe, fazlasıyla soğukkanlılık, sakin, rahat, duyguları biliyor ama hissedemiyor

Hoş,ilginç,gayet sevimli, soğukkanlı, duygusal açıdan kontrollü biri

Bay A

Dil, bellek, algılama,
hesap yapma,
NORMAL

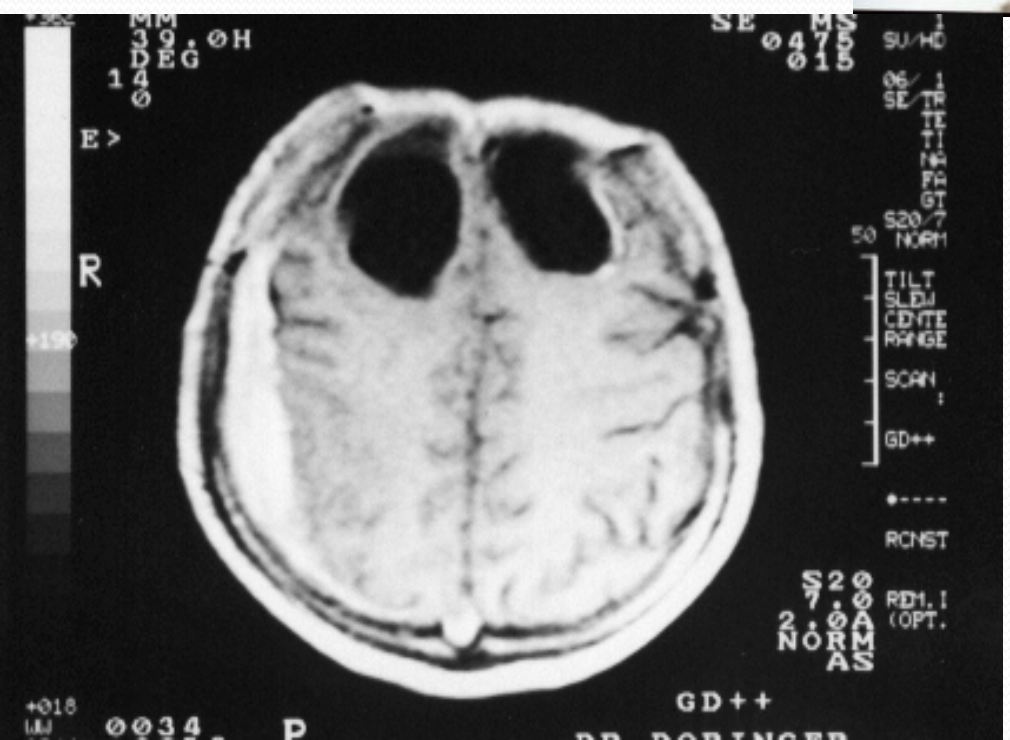

Kendi çıkarlarını
düşünememe

Gözüpeklik

Müstehcen konuşmalar

Fazlasıyla sakinlik

Ani sinirlenmeler

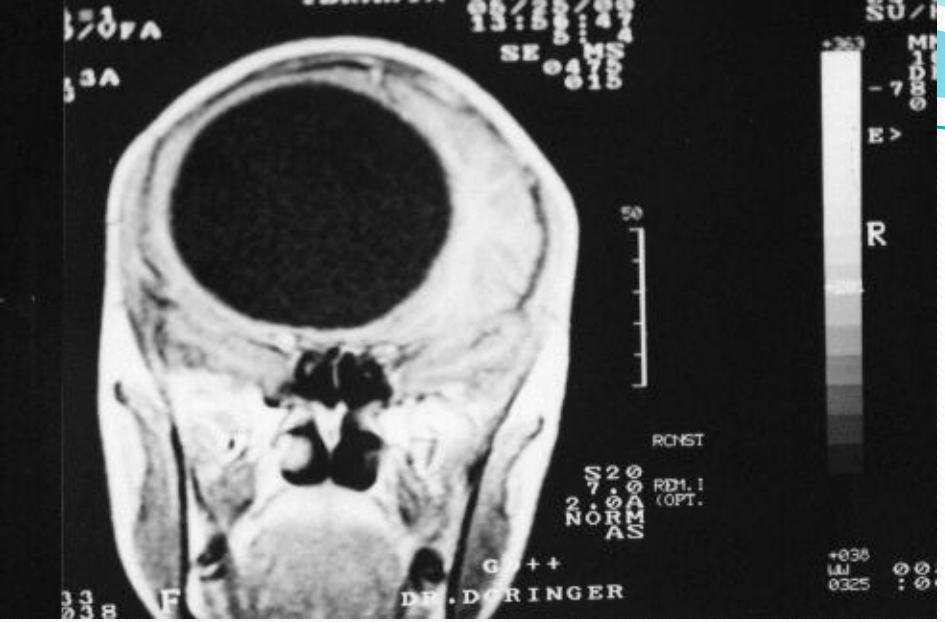

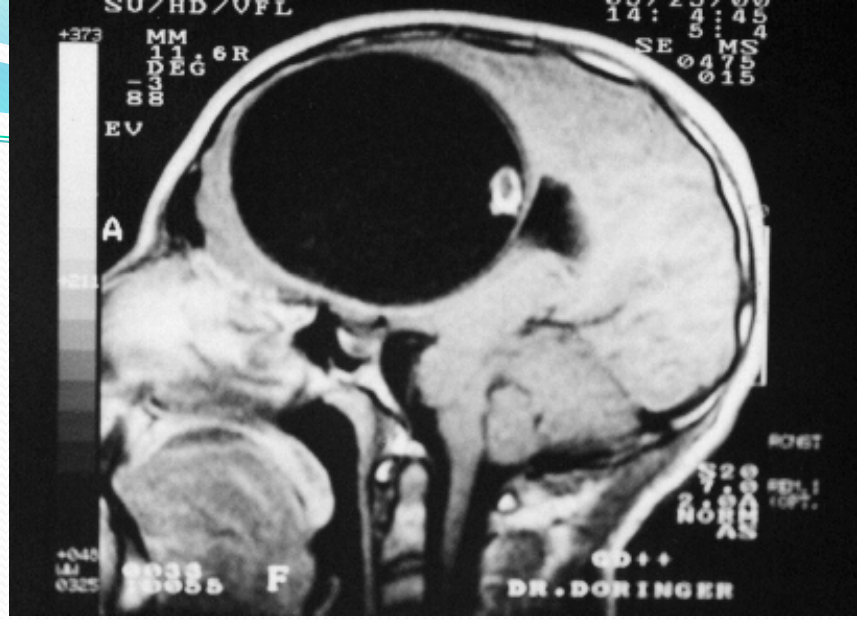

Dr.Nazan Aydın-Duyguların Anatomisi

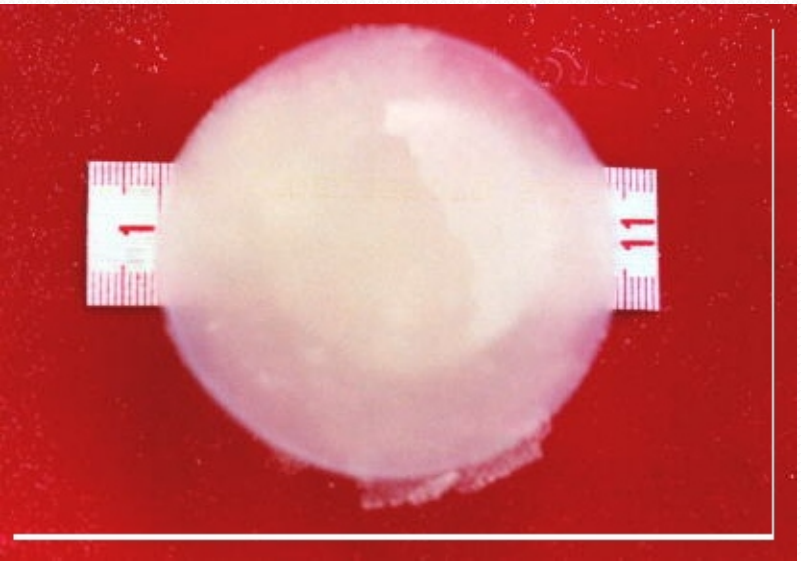

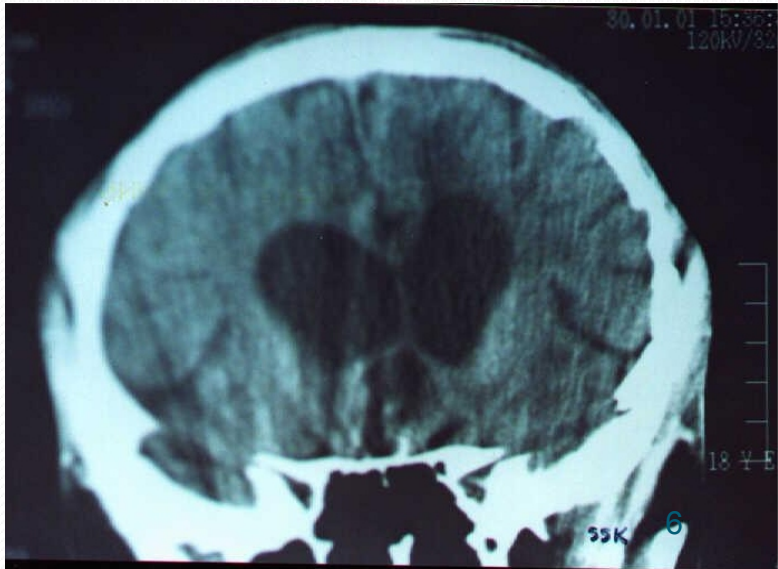

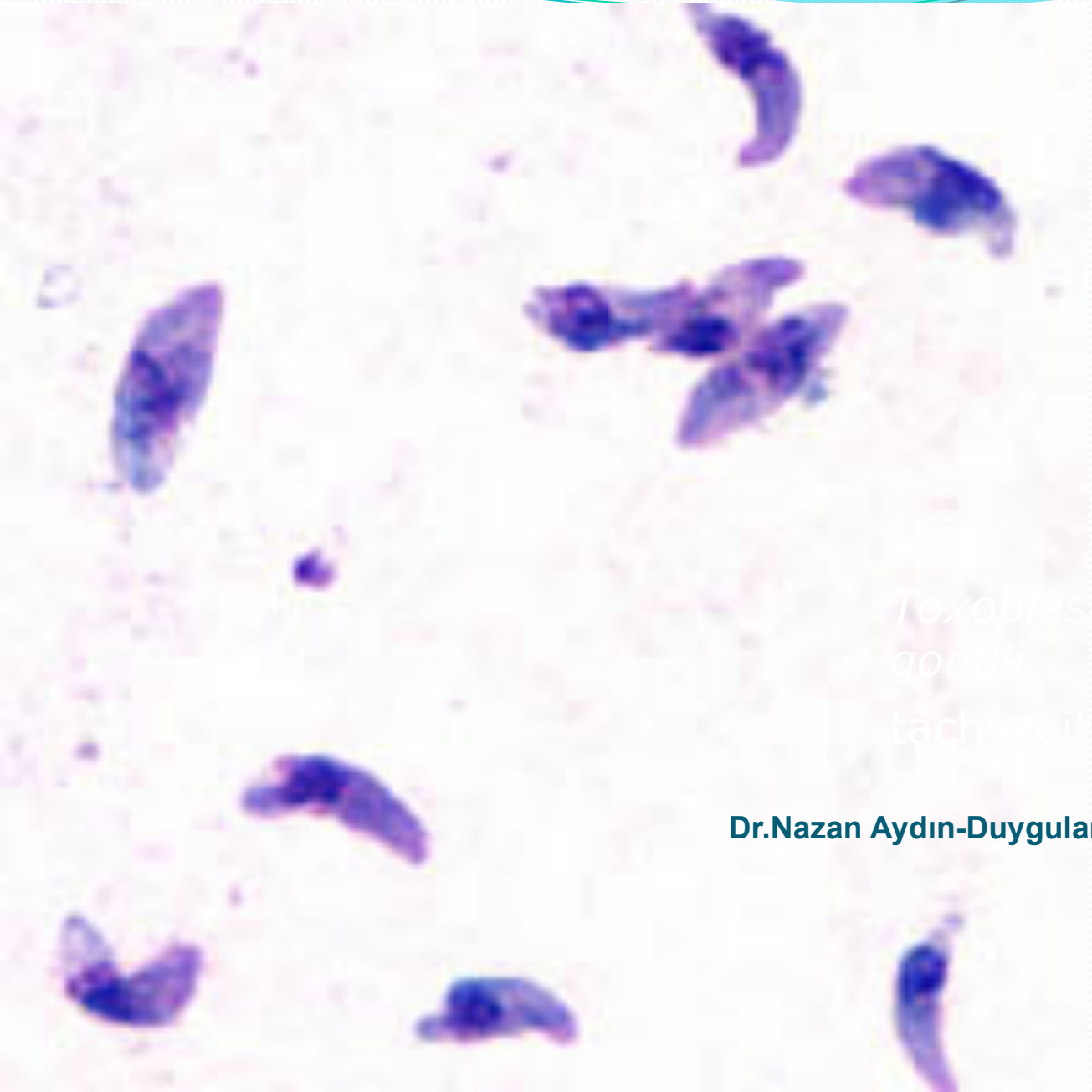

Toxoplasma gondii

tachyzoites



Bu parazitin son konağı, sadece evcil ve vahşi kedigillerdir.

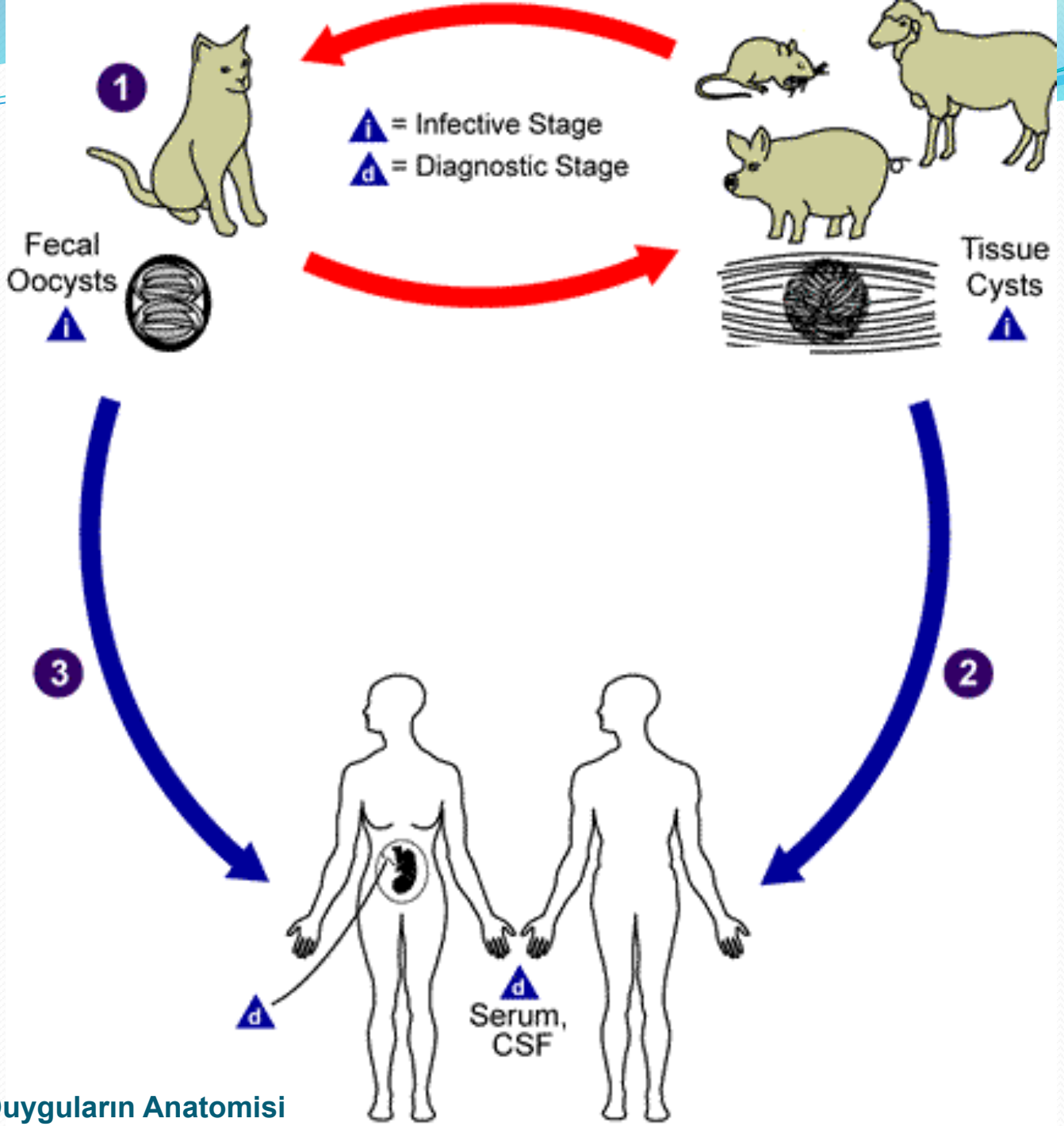
1
i = Infective Stage
d = Diagnostic Stage
Fecal
Oocysts
i
Tissue
Cysts
i
3
2
d
d
Serum,
CSF

(Berdoy ve ark. 2000)

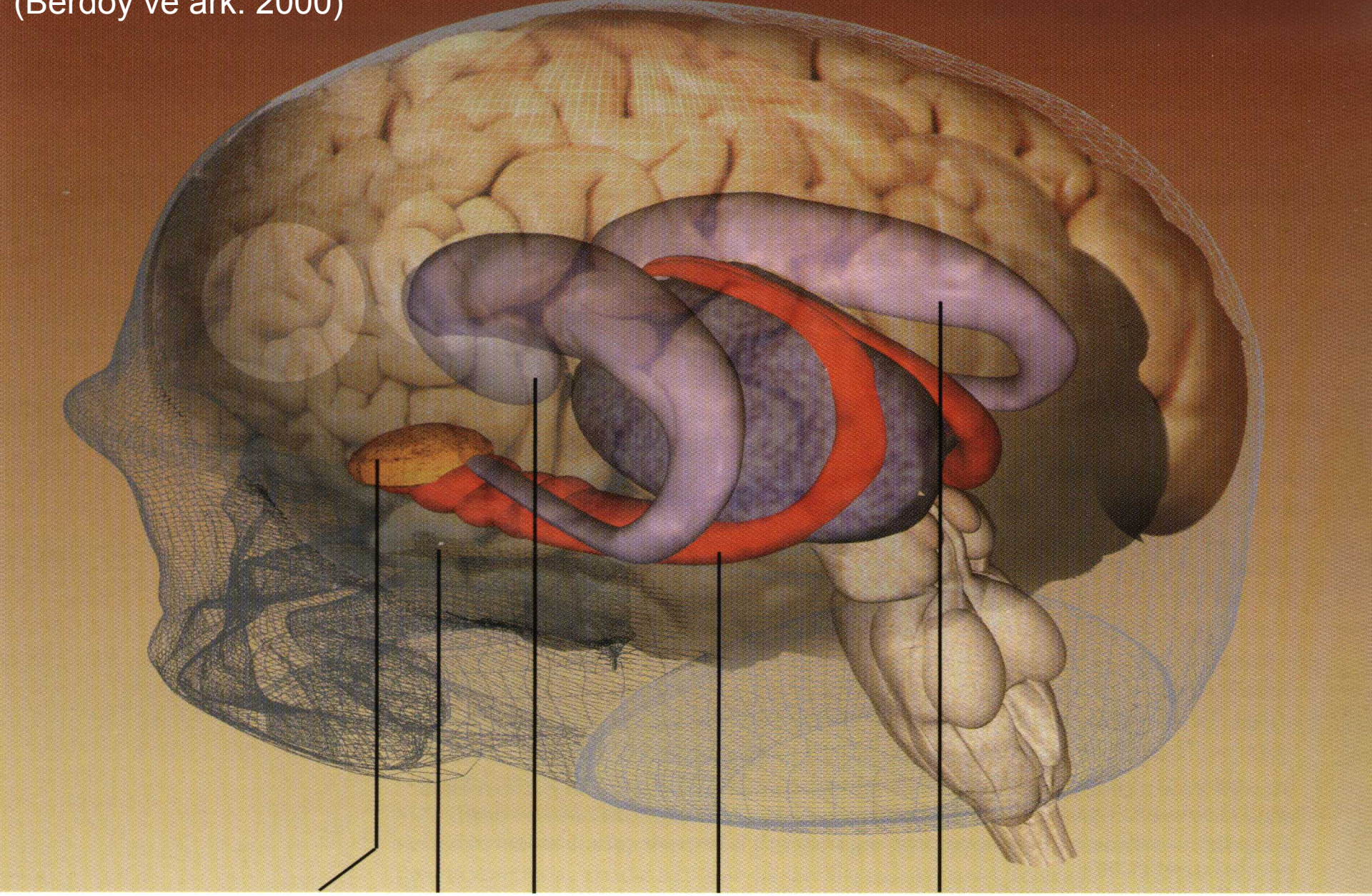

ANOSOGNOSİA

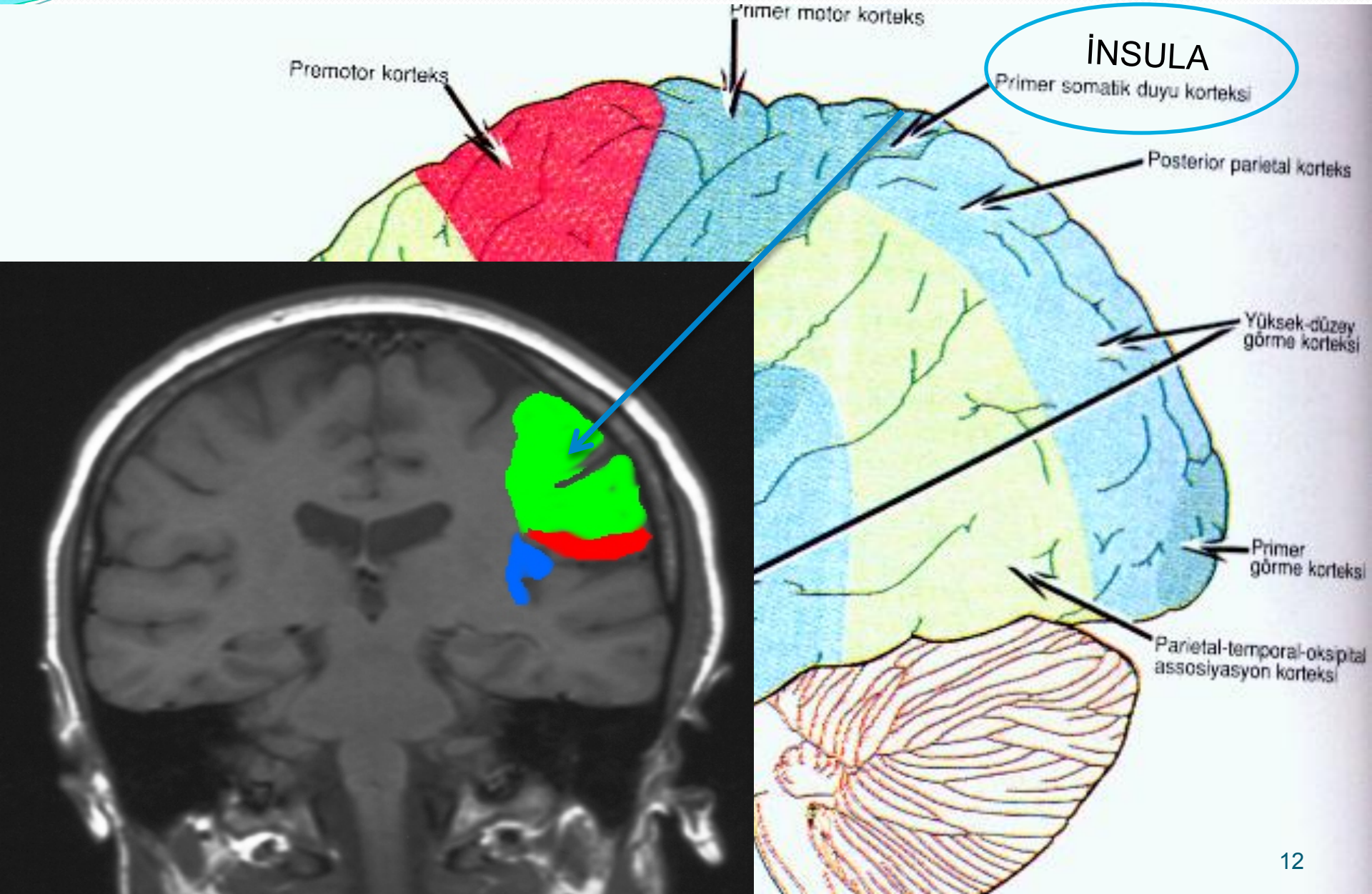

ASKIYA ALINMIŞ CANLILIK

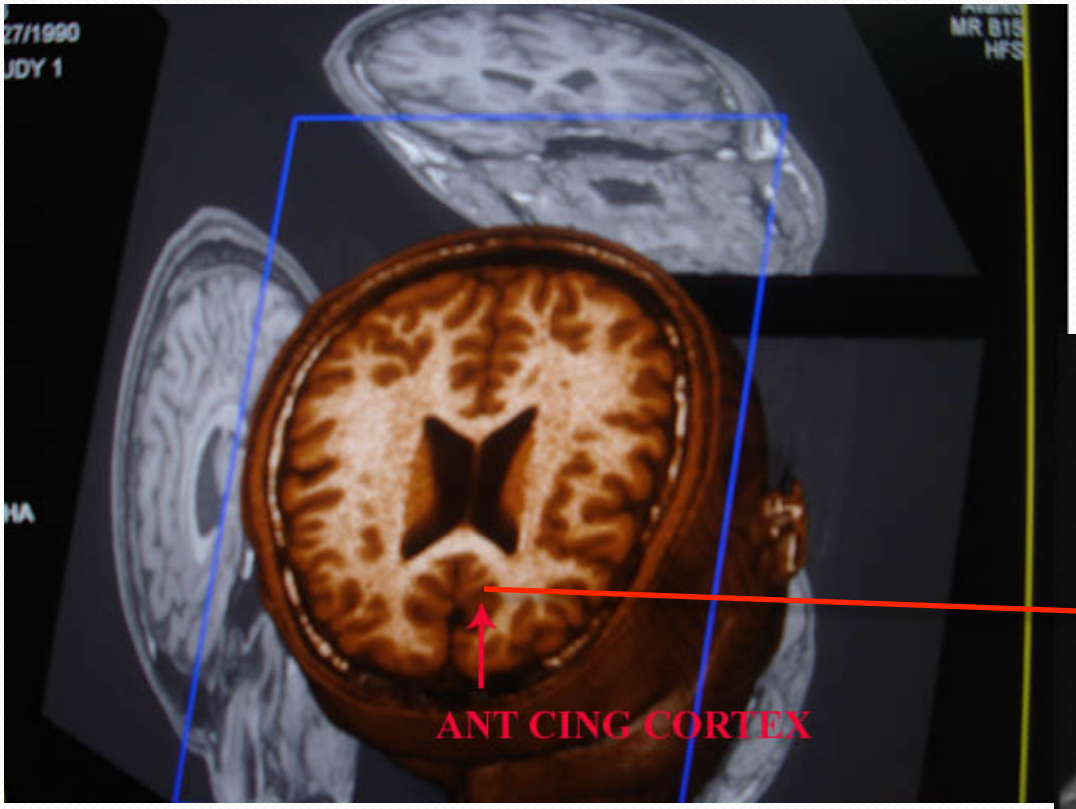

SUPLEMENTER
MOTOR ALAN
(M1+M2+M3)

Dr.Nazan Aydın-Duyguların Anatomisi

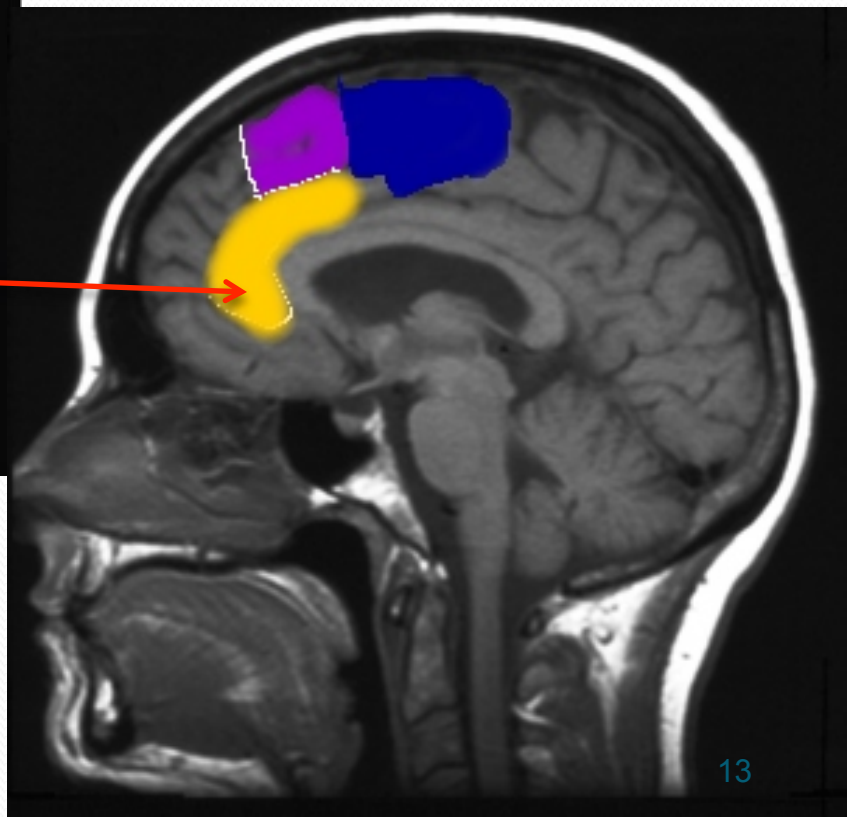

Anatomical Connectivity of the Subgenual Cingulate Region Targeted with Deep Brain Stimulation for Treatment-Resistant Depression.
Cerebral Cortex June 2008,



Voluntary smile circuit

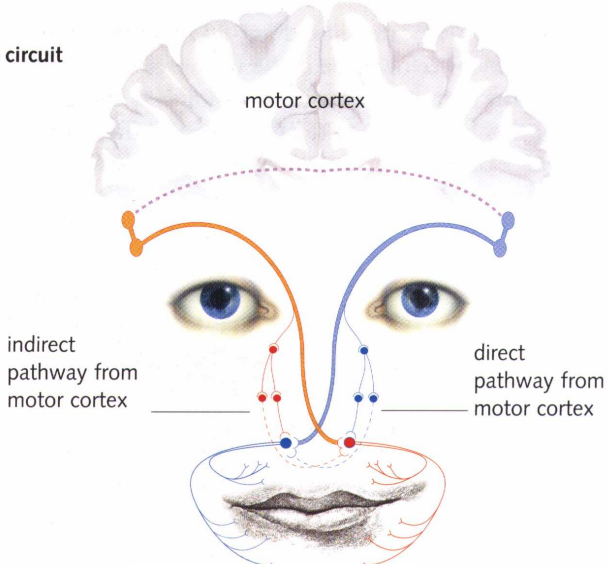

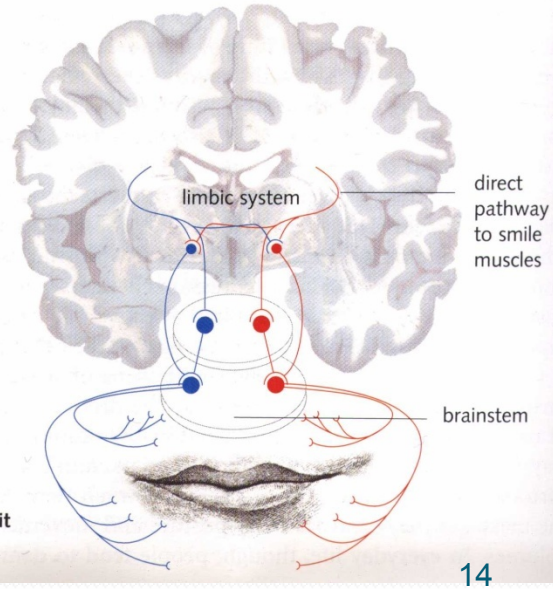

Spontaneous smile circuit

Background

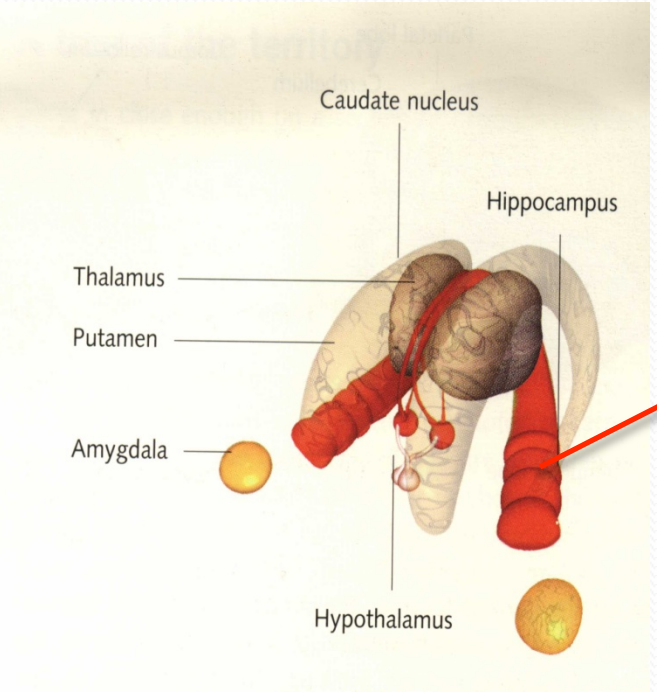
Caudate nucleus
Hippocampus
Thalamus
Putamen
Amygdala
Hypothalamus

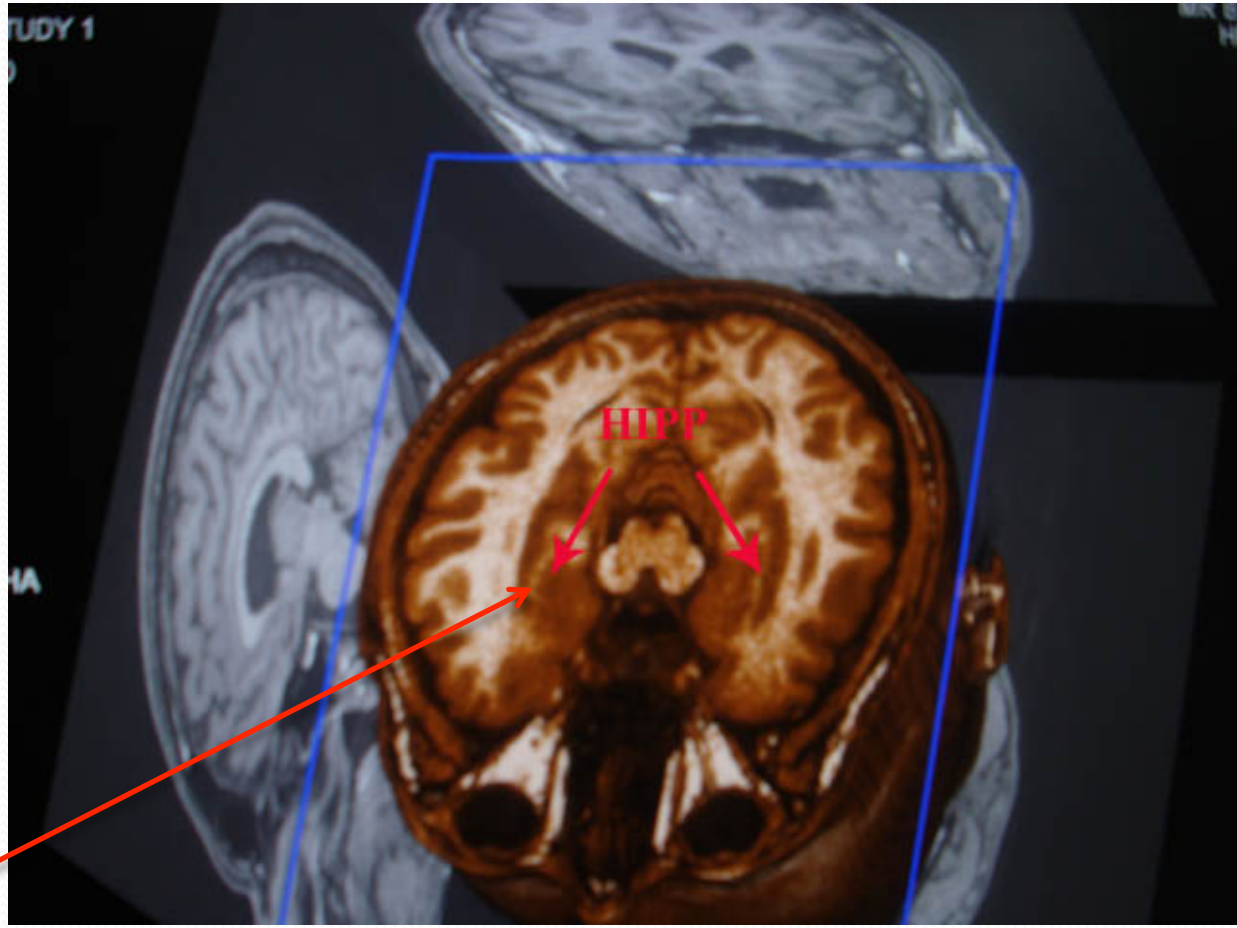
HIPP

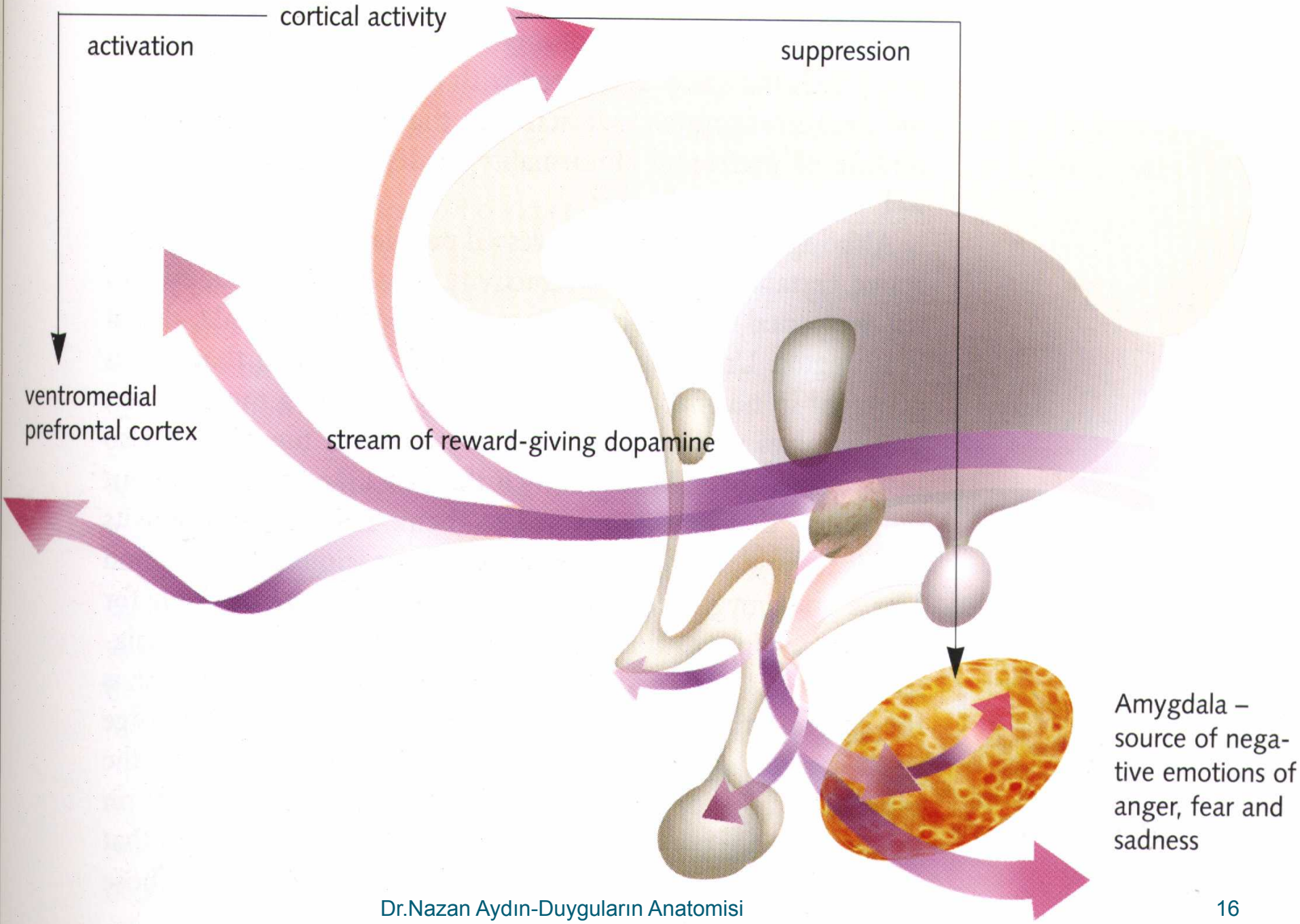
cortical activity
activation
suppression
ventromedial
prefrontal cortex
stream of reward-giving dopamine
Amygdala –
source of nega-
tive emotions of
anger, fear and
sadness

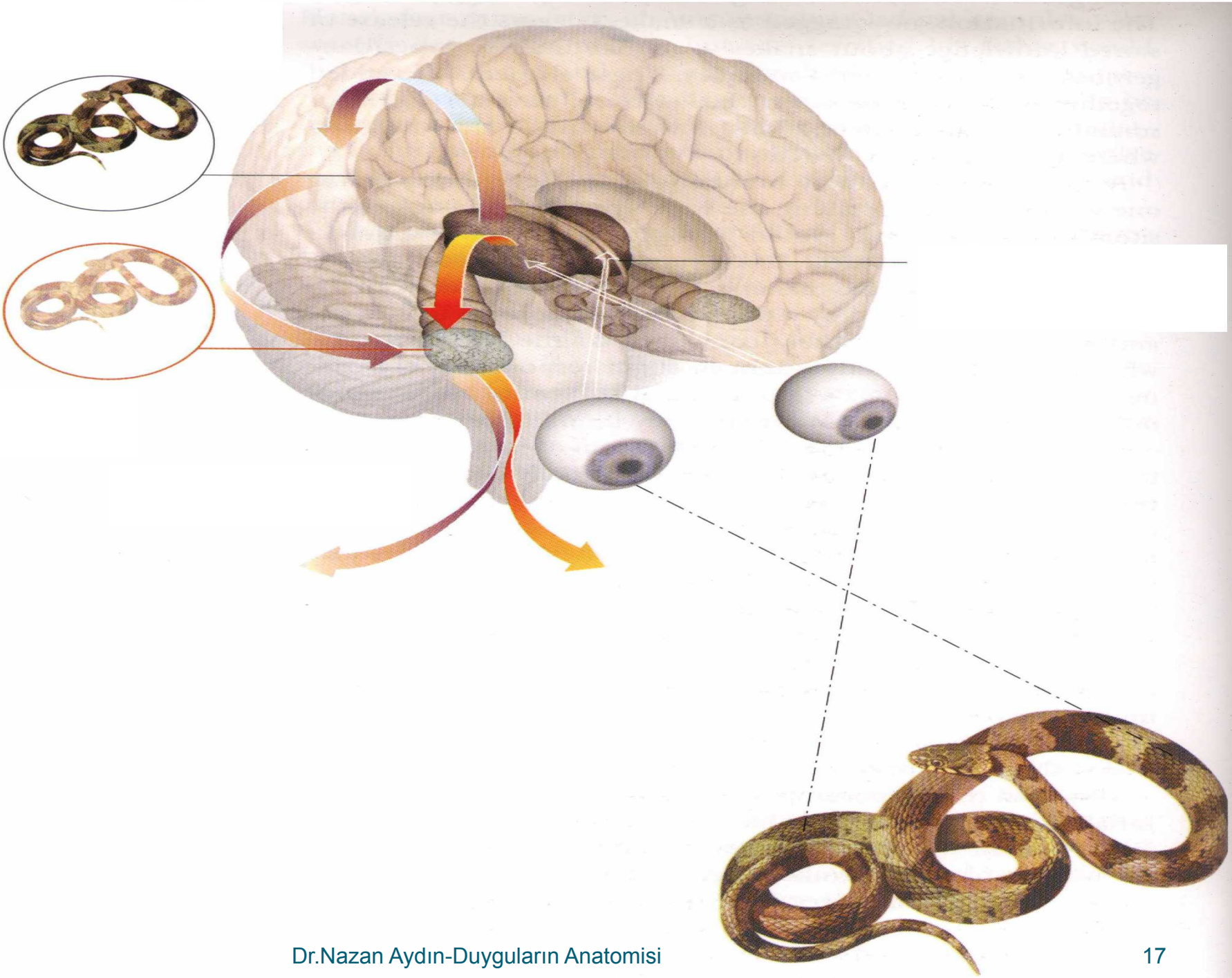

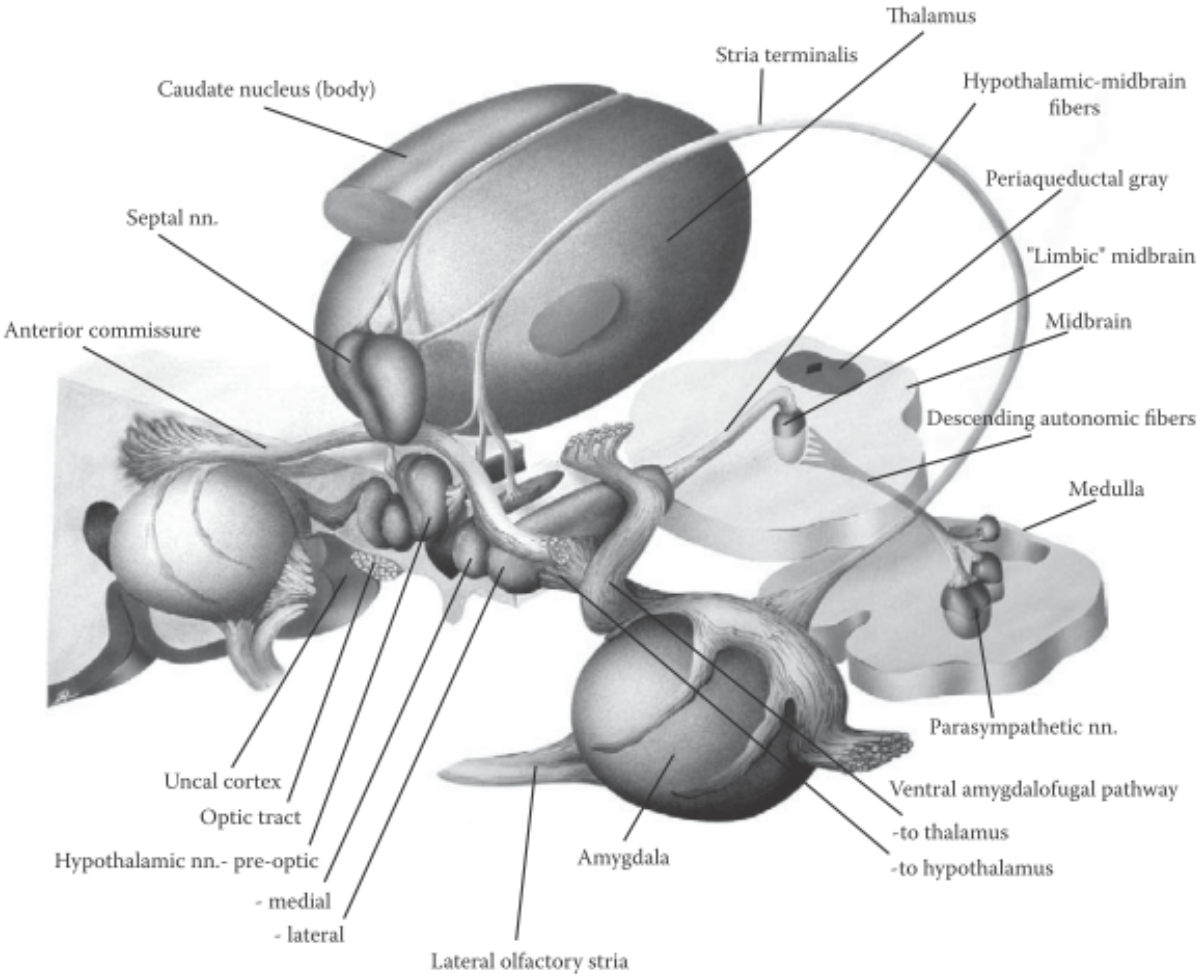
Thalamus
Stria terminalis
Caudate nucleus (body)
Hypothalamic-midbrain fibers
Periaqueductal gray
Septal nn.
"Limbic" midbrain
Midbrain
Anterior commissure
Descending autonomic fibers
Medulla
Parasympathetic nn.
Uncal cortex
Ventral amygdalofugal pathway
Optic tract
-to thalamus
Hypothalamic nn.- pre-optic
Amygdala
-to hypothalamus
- medial
- lateral
Lateral olfactory stria

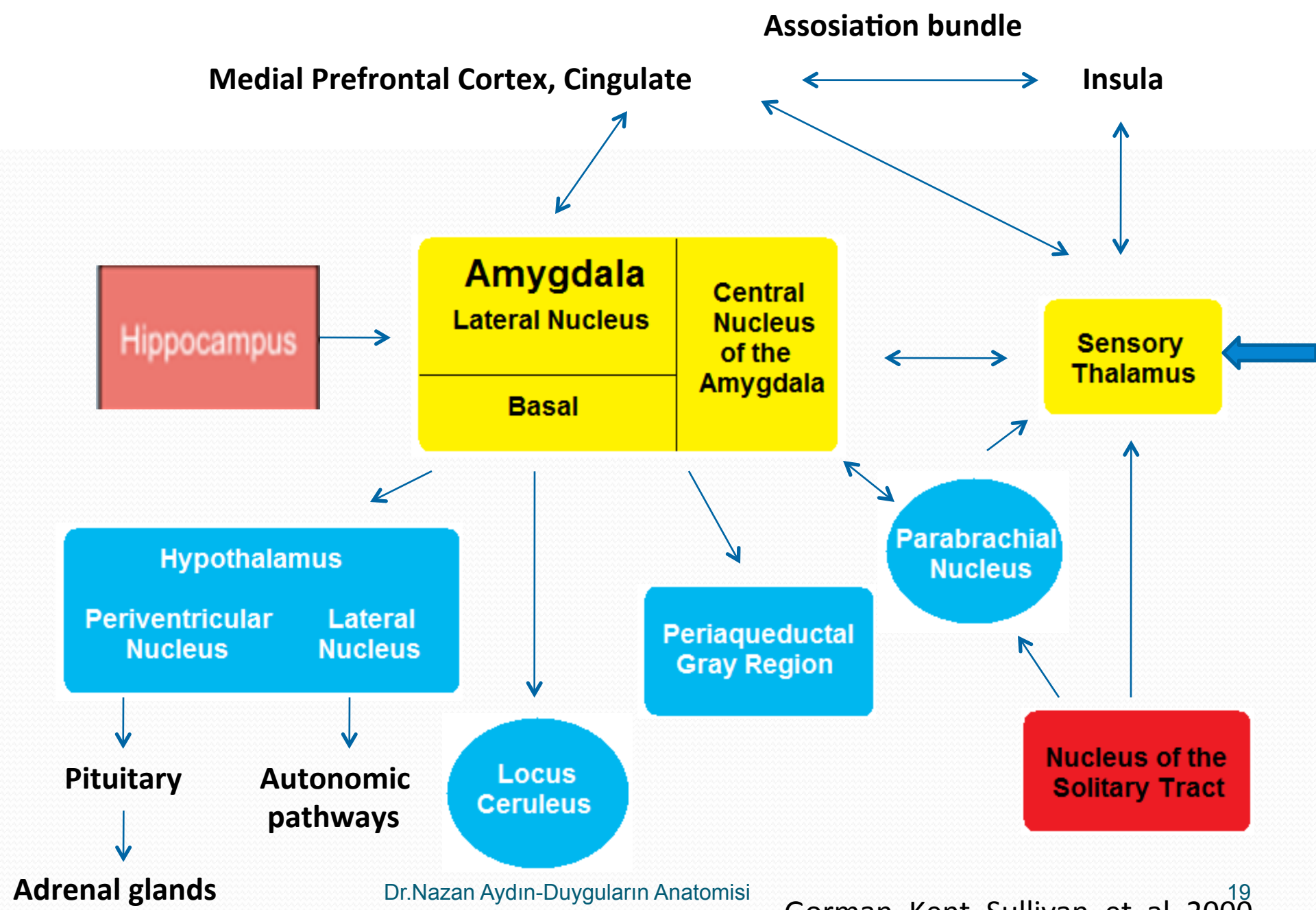

Gorman, Kent, Sullivan, et al. 2000

C

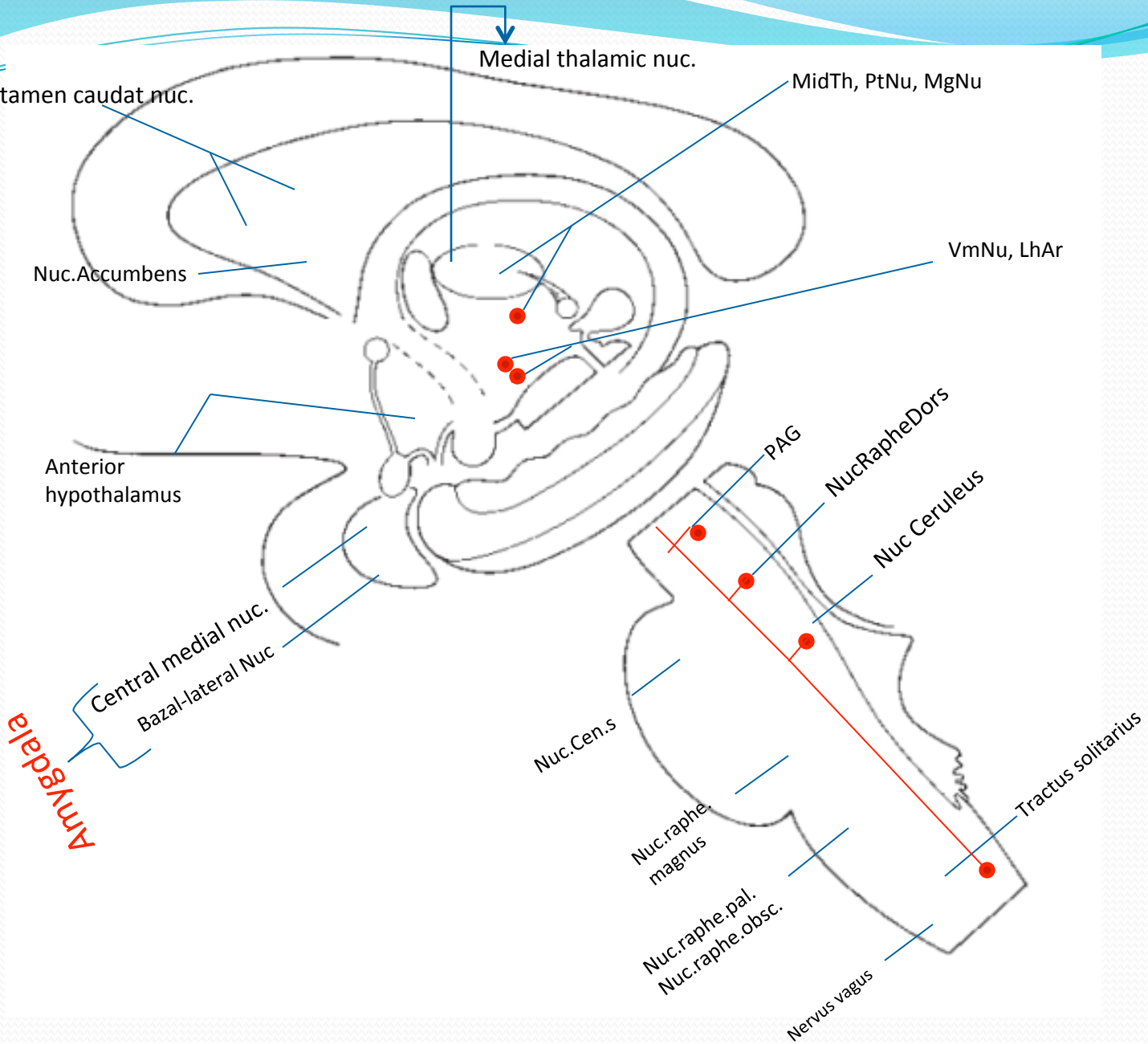
Medial thalamic nuc.
Putamen caudat nuc.
MidTh, PtNu, MgNu
Nuc.Accumbens
VmNu, LhAr
Anterior
hypothalamus
PAG
NucRapheDors
Nuc Ceruleus
Central medial nuc.
Bazal-lateral Nuc
Amygdala
Nuc.Cen.s
Tractus solitarius
Nuc.raphe.
magnus
Nuc.raphe.pal.
Nuc.raphe.obsc.
Nervus vagus

Panic disorder

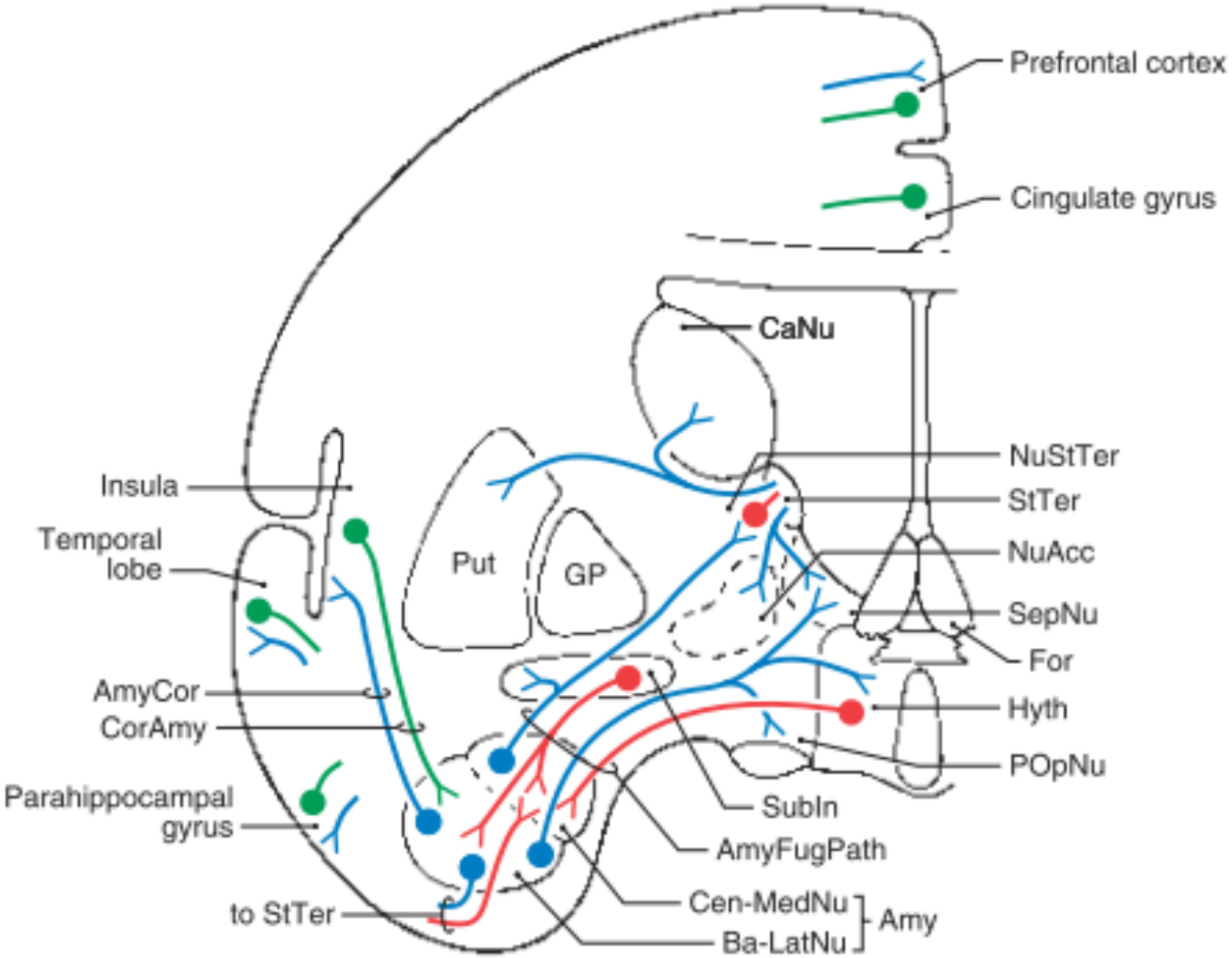

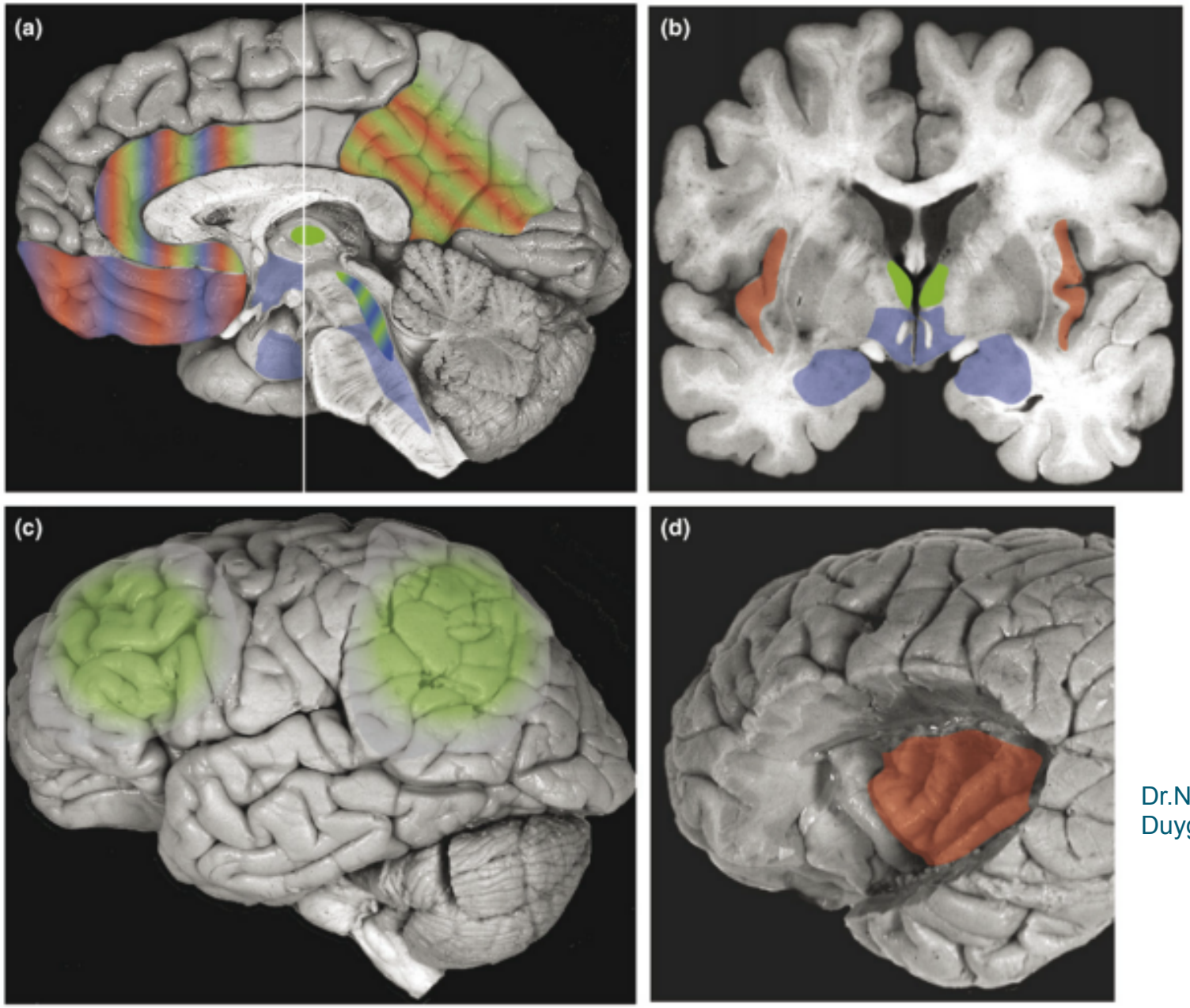

TRENDS in Cognitive Sciences

Figure 2. Brain regions that are important for emotion state (blue), feeling of emotion (red) and level of consciousness (green). Other components of an emotion state, and the content of consciousness, are presumed to rely on more variable and distributed structures that would depend on the particular kind of emotion or conscious experience and, therefore, are not depicted here. **(a)** Sagittal view shows that the hypothalamus, amygdala, brainstem nuclei, including periaqueductal gray and

Dr.Nazan Aydın-
Duyguların Anaton

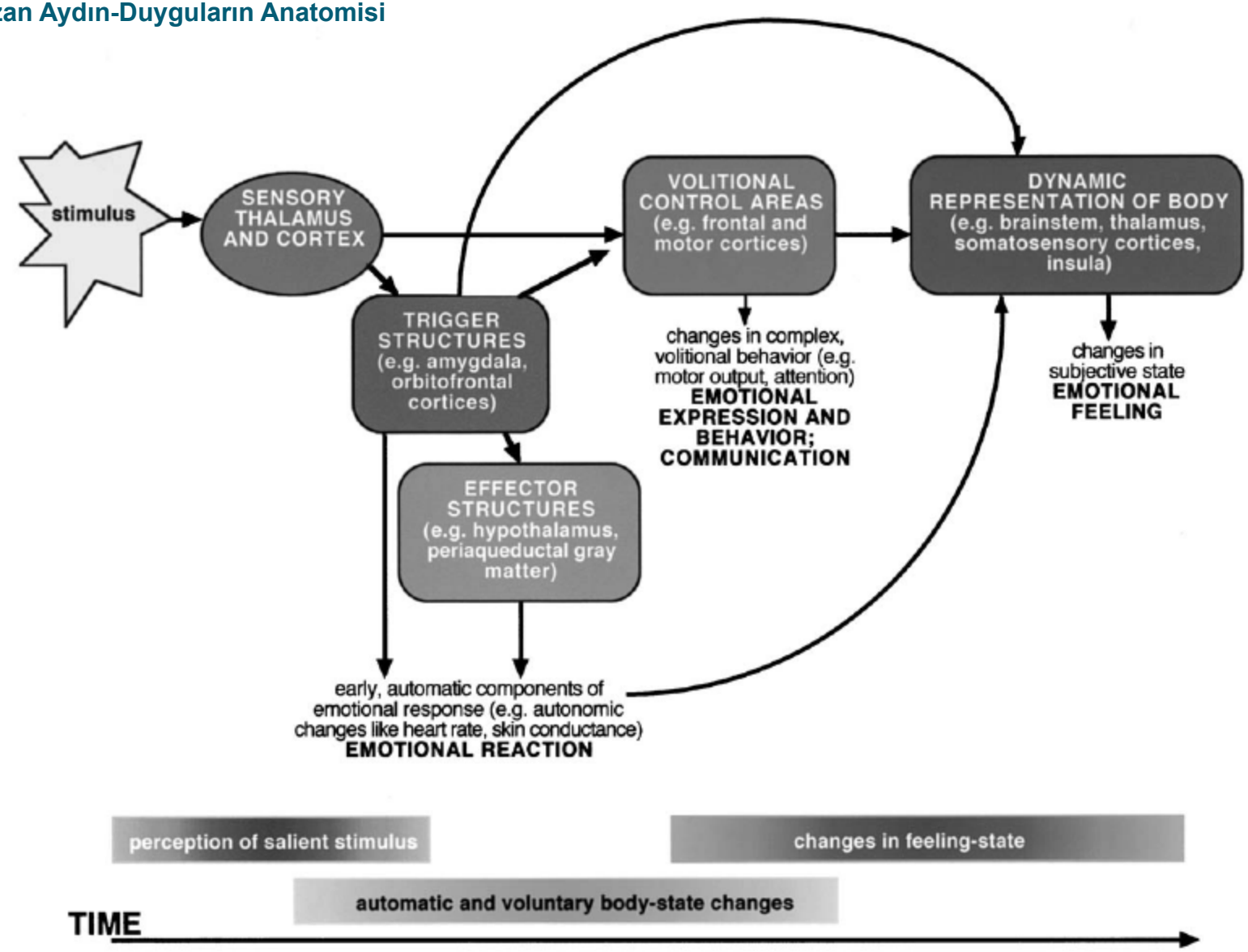

Figure 1 Time line relating the different components of emotion. A stimulus is perceived via a sensory organ, in most cases relayed through the thalamus to sensory cortex. The amygdala and other trigger structures receive projections from thalamus and from sensory cortex at many different levels. These trigger structures then project both to effector structures, such as hypothalamus, that effect changes in autonomic and endocrine activity and to volitional control areas, which are responsible for motor behavior and higher order cognition. All of these areas also project to areas which represent the body state and contribute to the subjective experience, or feeling, of emotion.