



## Research Article

### Haloperidol-Induced Neuronal Damage in Guinea Pig Hippocampus: A Microscopic Study

Elvan OZBEK<sup>1</sup>, B. Zuhall ALTUNKAYNAK<sup>2</sup>, Mehmet D. AYDIN<sup>3</sup>, Nazan AYDIN<sup>4</sup>, Ozgen VURALER<sup>1</sup>, Bunyamin UNAL<sup>1</sup>

<sup>1</sup>Departments of Histology and Embryology, Medical School, Ataturk University, Erzurum, Turkey <sup>2</sup>Department of Histology and Embryology, Medical School, Ondokuz Mayıs University, Samsun, Turkey <sup>3</sup>Departments of Neurosurgery, Medical School, Ataturk University, Erzurum, Turkey <sup>4</sup>Departments of Psychiatry, Medical School, Ataturk University, Erzurum, Turkey

#### Summary

Haloperidol, a neuroleptic drug, is still discussed if it is neurotoxic. In the present study, neurotoxic effects of haloperidol on guinea pig hippocampus were examined. Sixteen guinea pigs were randomly divided into two groups of 8 animals each. The animals of treatment group were given intraperitoneally (i.p.) haloperidol diluted in saline (dose of 5 mg/kg daily) for 6 weeks. Control animals received only the same volume of saline i.p. Hippocampi from both groups were examined by light and electron microscope. Numerous dark neurons with a heterochromatic nucleus and dense cytoplasm were observed in the hippocampi of the treatment group by light microscope and ultrastructural levels. Also some neurons have increased vacuolar contents and lysosomes. These findings suggest that haloperidol leads to prominent damage of hippocampal neurons.

**Key words:** Haloperidol, Hippocampus, Guinea Pig, Light Microscopy, Electron Microscopy

### Haloperidol Kobay Hipokampusunda Nöronal Hasar Oluşturur: Mikroskopik Bir Çalışma

#### Özet

Nöroleptik olarak kullanılan haloperidol adlı ilacın nörotoksik olup olmadığı halen tartışılan bir konudur. Bu çalışmada haloperidolün kobay hipokampusu üzerinde oluşturabileceği olası toksik etkiler araştırıldı. Çalışma için 16 adet kobay iki gruba ayrıldı. Her iki grupta yer alan sekiz kobaya 6 hafta boyunca hergün eşit hacimde serum fizyolojik (kontrol) ya da 5 mg/kg haloperidol (deney) intraperitoneal olarak yapıldı. Deney sonunda tüm deneklerden elde edilen hipokampus örnekleri ışık ve elektron mikroskopik düzeyde incelendi. Deney grubu örneklerinde çok sayıda koyu boyanmış ve heterokromatik nükleuslu çalışmadan elde edilen bulgulara göre haloperidolün hipokampus üzerinde toksik hasara yol açabileceği söylenebilir. Ayrıca bu nöronlardan bazılarının vakuoler içeriği ve lizozomları artmıştı. Bu çalışmadan elde edilen sonuçlara göre haloperidolün hipokampus üzerinde nörotoksik etkiye sahip olabileceği söylenebilir.

**Anahtar Kelimeler:** Haloperidol, Hipokampus, Kobay, Işık Mikroskopi, Elektron Mikroskopi

#### INTRODUCTION

Antipsychotic agents in the central nervous system have been considered to play an

important role in modulation of mental diseases. Various clinical<sup>(10,14)</sup> and experimental<sup>(3)</sup> studies have been carried

out the effects of different neuroleptic drugs which are considered to affect via neurotransmitter systems<sup>(8)</sup> It has been continuing the discussions about both effect mechanisms<sup>(21)</sup> but discussions about clinical results<sup>(35)</sup> of these drugs are continuing up to now.

Haloperidol (HAL) that is known as a dopamine receptor antagonist and sigma receptor-active neuroleptic<sup>(2)</sup> is a potent typical antipsychotic to be frequently used in-patients with schizophrenia to medication the behavioral disturbances<sup>(30)</sup>. About its mechanism, reported that hypersensitivity of dopamine receptors<sup>(4)</sup> or a decrease in the activity of glutamic acid decarboxylase, GABA-synthesizing enzyme, following long-term administration of antipsychotic drugs may contribute to the drug-induced antipsychotic's extrapyramidal effects<sup>(6)</sup>

Although It has been obtained a lot of useful information from different type studies such as structural<sup>(12)</sup> ultra structural<sup>(34)</sup> quantitative<sup>(25)</sup> and clinical<sup>(6)</sup> etc. Numerous previous studies are present about effects of haloperidol<sup>(23,28)</sup> and only two of them are ultrastructural hippocampal studies<sup>(17,32)</sup>. And introduced immediately after learning, haloperidol shows a tendency towards deterioration in the phase of memory consolidation<sup>(29)</sup>

The hippocampal region is an essential component of learning and memory processes<sup>(13)</sup> and has been shown to be damage by a number of toxicants<sup>(15,24,36)</sup> some of which are neuroleptic agents<sup>(1-7)</sup>

In the present study, we attempted to examine possible neuronal changes in guinea pig hippocampus following haloperidol treatment by comparing with those of the control group by light and electron microscopy.

## MATERIAL AND METHODS

### Experimental design and applying the drug.

The Ethical Committee of Ataturk University Hospital approved this study.

Sixteen adult male guinea pigs were used in this study. All animals were maintained under standardized conditions of light and temperature, with tap water.

The experimental animals were divided in to 2 groups (8 pigs per group). All the animals were treated simultaneously according to the following conditions; I)It given haloperidol 5 mg/kg/day for first group (n:8) calling that is chronic administration; ii) )It given saline at equal volume (n:8) calling that is the control group, respectively. Experimental drug or saline treated animals were injected i.p daily for 6 weeks.

### Perfusion and fixation

At the end of applying, all animals were anaesthetized via a short inhalation of ether, and then were fixed. Initially 0.9% saline (30 ml) solution was given intracardially followed by a mixture of 2% paraformaldehyde+2% glutaraldehyde (150 ml) in 0.1 M phosphate buffer, pH 7.4 at room temperature, for approximately 30 min.

Brains were removed and stored in the same fixative overnight at 4 °C. On the following day, the hippocampus in each brain was dissected out as described previously<sup>(11,31)</sup>. The hippocampal samples belonging to the each animal were embedded separately.

### Microscopy for histopathological examination at ultrastructural level

The hippocampal samples were processed; post fixed in 1% osmium tetroxide for 1 h, dehydrated through a graded alcohol series and embedded in Epon resin for ultrathin sections. Ultra thin sections with a gold interference colour were obtained using an ultramicrotome equipped with a diamond knife and were mounted on grids coated with formvar support film. From each block, approximately 30 serial sections were collected on ten grids. These grids containing sections were taken from three different regions of the blocks, which are called S1, S2 and S3. S1, S2 and S3 were

the proximal, medial and distal level of the embedded tissue in the block, respectively.

The section were stained with uranyl acetate and lead citrate and viewed using a JEM-100SX electron microscope. Then It was taken electron micrographs of these specimen at X5000 magnification to examine the morphologic changes of neuron histopathologically.

### **Microscopy for histopathological examination at structural level**

After the hippocampal samples to be received for applying of stereological method and histopathological examination were blocked as above, semi-thin sections (1 µm) were cut serially with a Nova LKB Bromma ultratome, and stained with toluidine blue. Also histopathological photographs were obtained under a light microscope with camera attachment (Olympus BX 51, JAPAN).

## **RESULTS**

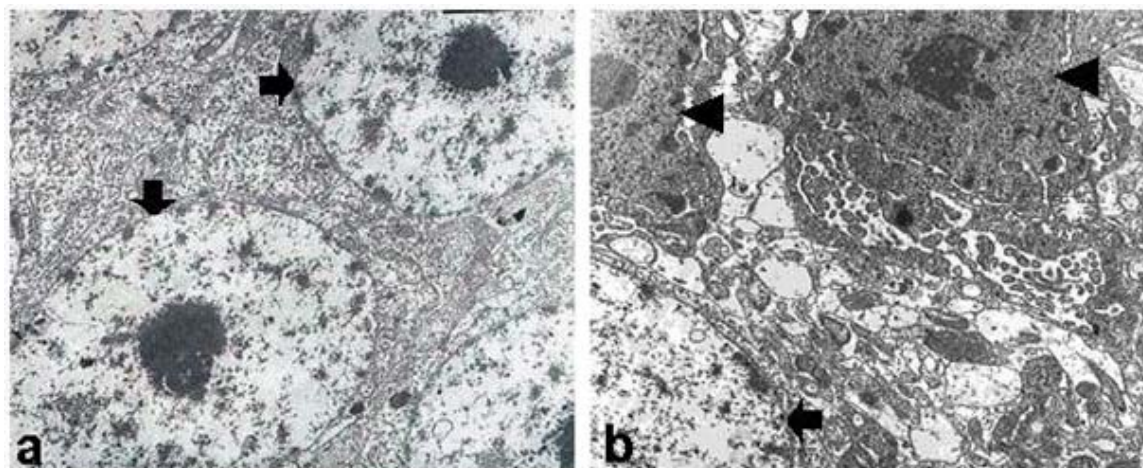
### **Histopathological results at ultrastructural level**

In the control animals, the cell body of neurons was usually large, dilated region of the cell that contain a large, euchromatic

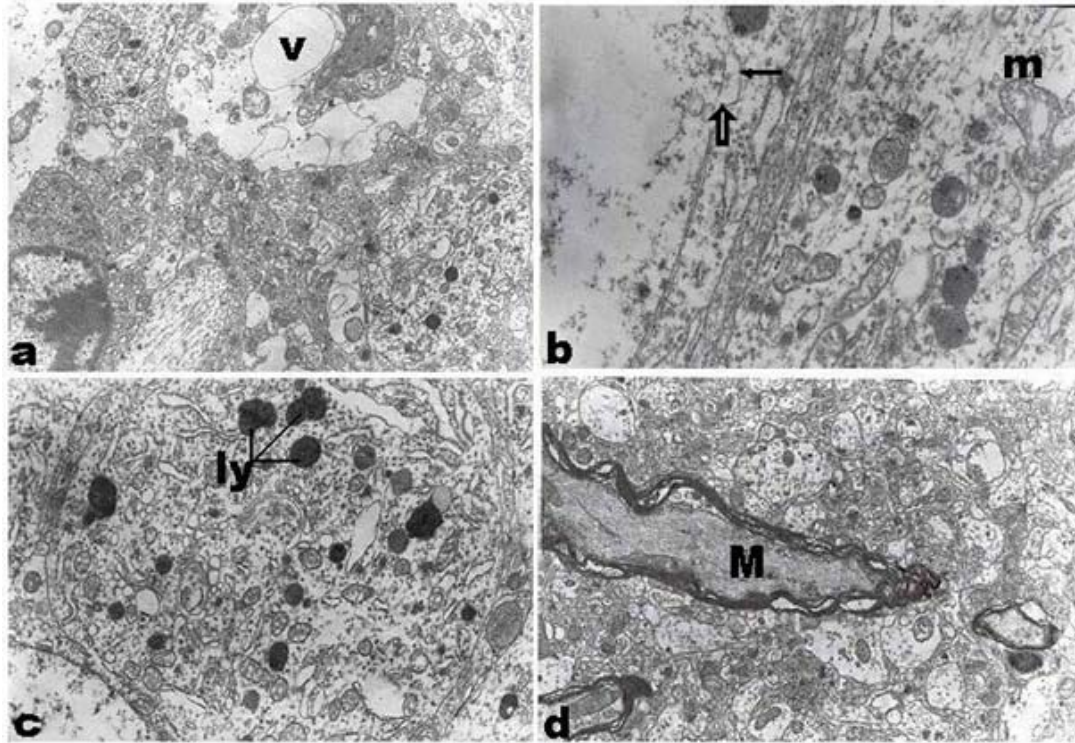
nucleus with one or two prominent nucleoli. The perikaryon also had masses of free ribozomes, profiles of granular endoplasmic rediculum (GER), lysosomes, numerous mitochondria, and a large perinuclear Golgi organelle (Figure 1a).

It observed some difference according to control group in first group calling that is acute administration. Most of neurons were clearly determined smaller nuclei compared to that of control.

In second and third groups calling that is chronic administration, It was established increasing of amount of ultrastructural changes. It was seen the dark neuron with the dens nucleus (Figure 1b), increasing the lipofuscin granules, abundant lysosomes (Figure 2c), especially third groups of which are. In addition, perinuclear edema and large vacuolar structures appeared clearly in perikaryon (Figure 2a) and the distance between the inner and outer nuclear membrane was enlarged (Figure 2b), and the inner nucleus membrane fragmented in some areas (Figure 2b). Finally, distorted myelin sheaths were encountered in the second and third groups (Figure 2d).



**Figure 1:** Electron micrographs of the hippocampus in guinea pigs (a) Neuronal cell nucleus (black arrow), illustrating apparently normal ultrastructural morphology. (b) Electron micrographs of neuronal degeneration; two neuron in the guinea pig hippocampus that is given high dose haloperidol (5 mg/kg), exhibiting the increased condensation and margination of nuclear chromatin (arrow head) and one nucleus with normal shape (black arrow).



**Figure 2:** Electron micrographs of neuronal degeneration in the hippocampus of guinea pigs that is applied high dose, illustrating apparently abnormal ultrastructural morphology. which is contained (a) large vacuole (v), (b) swollen mitochondria (m), fragmentation (black arrow) and dilatation (white arrow) of nuclear envelope, (c) increased density of lysosomes (ly) and finally (d) degenerating myelin (M) profile

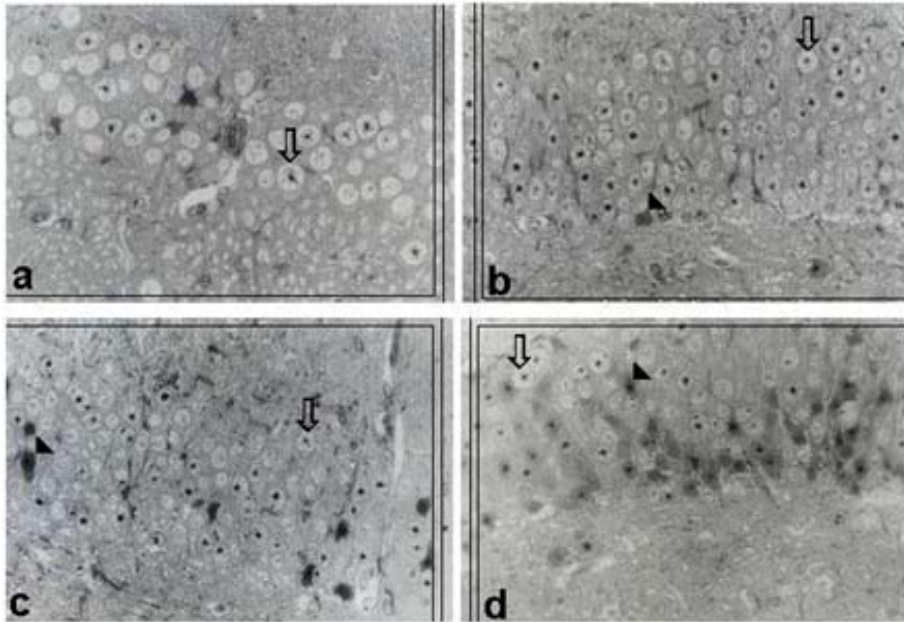
### **Histopathological results at structural level**

The histopathological findings in light microscope correlated well with the findings in electron microscope (Figure 3).

When It is compared the morphological changes of hippocampal neuron between control and first, second and third group. It determined some alternation toward necrosis such as swelling and clumping in nuclear chromatin and also observed pathological changes about nuclei of neurons such as condensation of chromatin and shrinkage of the nucleus (Pyknosis),

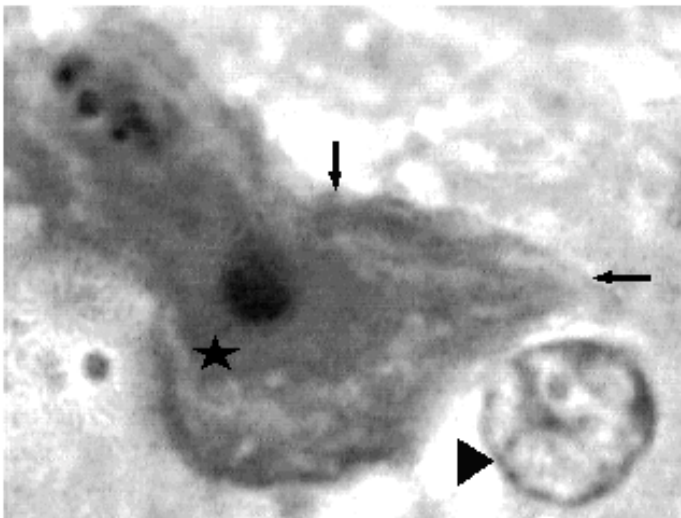
and fragmentation of the nucleus (Kayorrhexis) (Figure 4).

It was seen more dramatic changes in second and third groups calling that is chronic administration (Figure 3c,d). The amount of necrotic neurons increased both second and third group. It observed that the nucleolus is disappeared at most of neurons. At the same time, the nucleus displaced eccentrically and the cell body enlarged, causing conversion of its counter from concave to convex for especially second and third groups.



**Figure 3:** Light micrographs of the hippocampus in guinea pigs (a) Neuronal cell nucleus (arrow) in control group, illustrating apparently normal ultrastructural morphology. (b) In first group, gradually to be started increasing amount of degenerated neurons (arrowhead) (c) It seem like the first group arrangement neurons in the second group.

Although there is both normal and necrotic neuron, It was in favor of image of normal neuron (arrow) that is dominated the most of interesting area (d) In the third group, It was attracted attention increasing the number of necrotic neurons (arrowhead). Nucleus and cell body affected neurons are shrunken and lack morphologic detail.



**Figure 4:** Light micrograph of neuron one of which is affected (arrow), other has normal (arrowhead) structural shape apparently. It was observed clumping and condensation of chromatin and shrinkage of the nucleus and also nucleus was displaced peripherally, shrunken and darkly staining (asterisk). Internal details of ischemic neuron are obscured. Finally Cell counters are converted from concave to convex.

## DISCUSSION

Various clinical observations regarding the actions of neuroleptic drugs, which are one group of antipsychotic agents, have led to conjectures that these drugs may induce structural alterations in the brain. It has been purposed a lot of idea about the morphological effects in neuronal level of antipsychotic drugs.

Animal experiments have even indicated that haloperidol can damage cholinergic pathways<sup>(30)</sup>. Haloperidol may initiate a number of harmful effects on central nervous system neurons, including damage to cholinergic pathways on effect that could be especially deleterious to that experiencing memory dysfunction<sup>(30)</sup>

There are a lot of morphological studies about useful effect of neuroleptic agents such as neuroprotective and neurogenesis at microscopic level<sup>(35,5)</sup> but it has been mentioned by only some researcher that treatment with these agents have some side effects such neurodegeneration or neuronal cell loss<sup>(1,20)</sup> in some area of brain, for examples hippocampus, striatum, medial prefrontal cortex.

Our study was limited to only one time point for treatment (42 days), which was selected to correspond to most published studies on typical neuroleptic. In guinea pigs, a 42-day, chronic treatment period corresponds to about 6 years of treatment in patients<sup>(35)</sup>. Therefore, our results correspond to chronic haloperidol treatment in humans. Because it is unknown whether these effects of haloperidol are dependent dosage or not<sup>(37,22)</sup>. We aimed to evaluate effects of haloperidol on hippocampal neurons at different dosages.

In the low dose, Dawirs and colleagues have reported that the low dose treatment with haloperidol increases cell proliferation on hippocampus<sup>(5)</sup> but we could not encounter any mitotic figures at ultrastructural level. In addition, we could not find out any information by

stereological approach about more less neuronal height, to be thought an important evidence of mitosis in low dose treatment group. Briefly, there was not any abnormal morphological appearance neither structural and ultrastructural investigation nor morphometrical analysis

It has been reported that the addition of haloperidol to the cell culture medium reduced HT22 cell survival dose-dependently<sup>(27)</sup>. This finding also was reported for other cell lines and for rat primary cells<sup>(33)</sup>. Another study, Post et al. showed that haloperidol treatment in rats was associated with increases in the expression of p53 and the ratio of pro-apoptotic (Bax) to anti-apoptotic (Bcl-2/Bcl-x(L)) proteins in the hippocampus and caudate putamen (CPu)<sup>(26)</sup>

We showed a decrease of neuronal height, one of the most evident indicating cell deaths by using one of the stereological approaches in our previous study<sup>(31)</sup>. There was a significant decrease in mean neuronal height and we especially determined a significant difference statistically in neuronal height of high dose group, comparing with other two groups<sup>(31)</sup>.

Our findings at structural and ultrastructural level support to our stereological results. In toxic situations as known cytoplasmic swelling in neurons occurs owing to an impairment of the sodium pump mechanism at the cell membrane and they have proved that in cell swelling, the nuclear envelope, which is functionally continuous with the granular endoplasmic reticulum (GER), is also susceptible to osmotic damage resulting in membrane separation and cisternal dilatation<sup>(19,16)</sup>. We determined much important evidence of degenerations such as pyknosis in nucleus, the increases in cytoplasmic density and in the number of lysosomes and vacuolar structures, perinuclear edema (or cytoplasmic swelling), and distorted myelin sheaths

show that high doses of haloperidol caused hippocampal neurodegeneration (figure). we also saw that the perinuclear cistern between the inner and outer nuclear membranes was expanded, and the inner nuclear membrane was fragmented in some areas. It was determined that dark neurons were increased in number from first group to third, and the clear neurons with euchromatic nucleus were less in third group than those in other groups as have been declared by some scientists that haloperidol causes necrotic cell death in hippocampus<sup>(2,18)</sup>. The hypothesis that atypical neuroleptics (olanzapine and risperidon) stimulate neurogenesis<sup>(35)</sup> and the typical neuroleptic, haloperidol (0.4 mg/kg/day), does not stimulate neurogenesis<sup>(9)</sup> resemble with our findings. Although it has been claimed by some authors that haloperidol increase neurogenesis in the hippocampus<sup>(5)</sup>

It has been claimed a lot of findings about the morphological effects in neuronal level of antipsychotic drugs. The discrepancies in the results of these haloperidol studies might be due to differences in experimental designs, drug dosages, and the species studied.

In conclusion, our findings may support that high dose haloperidol is toxic to neurons. Especially, cognitive impairment may be a result of hippocampal neuron necrosis by high-dose chronic haloperidol treatment. In clinical settings, should be avoided from high dose neuroleptic treatment.

**Correspondence to:**

Bunyamin Unal

E-mail: [bunyamiunal@gmail.com](mailto:bunyamiunal@gmail.com)

**Received by:** 14 October 2009

**Revised by:** 17 September 2010

**Accepted:** 04 November 2010

**The Online Journal of Neurological Sciences (Turkish) 1984-2010**

This e-journal is run by Ege University  
Faculty of Medicine,

Dept. of Neurological Surgery, Bornova,  
Izmir-35100TR

as part of the Ege Neurological Surgery  
World Wide Web service.

Comments and feedback:

E-mail: [editor@jns.dergisi.org](mailto:editor@jns.dergisi.org)

URL: <http://www.jns.dergisi.org>

Journal of Neurological Sciences (Turkish)

Abbr: J. Neurol. Sci.[Turk]

ISSNe 1302-1664

**REFERENCES**

1. Bardgett ME, Humphrey WM, Csernansky JG. The effects of excitotoxic hippocampal lesions in rats on risperidone- and olanzapine-induced locomotor suppression. *Neuropsychopharmacology* 2002; 27: 930-8.
2. Behl C, Rupprecht R, Skutella T, Holsboer F. Haloperidol-induced cell death mechanism and protection with vitamin E in vitro. *Neuroport* 1995; 7: 360-4.
3. Broerse A, Timmerman W, Westerink BH, Den BJ. Antipsychotics and single-cell activity in the rat superior colliculus. *Prog Neuropsychopharmacol Biol Psychiatry*. 2002 Feb; 26(2): 327-33.
4. Clow A, Jenner P, Theodorou A, Marsden CD. Striatal dopamine receptors become supersensitive while rats are given trifluoperazine for six months. *Nature* 1979; 278: 59-61.
5. Dawirs RR, Hildebrandt K, Teuchert-Noodt G. Adult treatment with haloperidol increases dentate granule cell proliferation in the gerbil hippocampus. *J Neural Transm*. 1998; 105: 317-27.
6. Gale K. Chronic blockade of dopamine receptors by antischizophrenic drugs enhances GABA binding in substantia nigra. *Nature* 1980; 283: 569- 570.
7. Gepdiremen A, Aydin N, Halici Z, Sahin O, Unal B, Aydin MD, Bakuridze K. Chronic treatment of haloperidol causes vasoconstriction on basilar arteries of rats, dose dependently. *Pharmacol Res*. 2004; 50(6): 569-74.
8. Harrison PJ. The neuropathological effects of antipsychotic drugs. *Schizophr Res*. 1999; 40(2): 87-99.
9. Hildebrandt K, Teuchert-Noodt G, Dawirs RR. A single neonatal dose of methamphetamine suppresses dentate granule cell proliferation in adult gerbils which is restored to control values by acute doses of haloperidol. *J Neural Transm*. 1999; 106: 549-58.

10. Hirsch SR, Kissling W, Bauml J, Power A, O'Connor R. A 28-week comparison of ziprasidone and haloperidol in out patients with stable schizophrenia. *J Clin Psychiatry*. 2002; 63: 516-23.
11. Kaplan S, Gökyar A, Ünal B, Turkkani-Tunç A, Bahadır A, Aslan H. A simple technique for localizing consecutive fields for disector pairs in light microscopy: application to neuron counting in rabbit spinal cord following spinal cord injury. *Journal of Neuroscience Methods* 2005; 145: 277-284.
12. Kawagishi S, Yoshino K, Jones TE, Iwamoto M, Arai S, Amano N. Dopamine receptor antagonists increase markedly the quantity of retrograde transport of HRP in the rat masseteric motoneuron. *Brain Res* 1992; 585: 196-204.
13. Korbo L, Ladefoged O, Lam HR, Ostergaard G, West MJ, Arlien-Soborg P. Neuronal loss in hippocampus in rats exposed to toluene. *Neurotoxicology* 1996; 17(2): 359-66.
14. Labelle A, Light M, Dunbar F. Risperidone treatment of outpatients with schizophrenia: no evidence of sex differences in treatment response. *Can J Psychiatry*. 2001; 46(6):534-41.
15. Lawston J, Borella A, Robinson JK, Whitaker-Azmitia PM, Schurr A, West CA, Rigor BM. The excitotoxicity of heterocyclic dicarboxylic acids in rat hippocampal slices: structure-activity relationships. *Brain Res*. 1992; 571(1): 145-8.
16. Lezoualc'h F, Rupperecht R, Holsboer F, Behl C. Bcl-2 prevents hippocampal cell death induced by death induced by the neuroleptic drug haloperidol. *Brain Res*. 1996; 738: 176-9.
17. Makliakov IuS, Karkishchenko NN, Bardakhch'ian EA, Kharlanova NG. (Ultrastructural basis of the effect of haloperidol on the brain) *Zh Nevropatol Psikiatr Im S S Korsakova*. 1992; 92(4): 81-8.
18. Malberg JE, Eisch AJ, Nestler EJ, Duman RS. Chronic antidepressant treatment increases neurogenesis in adult rat hippocampus. *J Neurosci*. 2000; 20(24): 9104-10.
19. McGee JO'D, Isaacson PG, Wright NA. *Oxford Textbook of pathology, Volume 1*. Oxford: Oxford University Press, 1992: 142-80.
20. Mitchell IJ, Cooper AC, Griffiths MR, Cooper AJ. Acute administration of haloperidol induces apoptosis of neurones in the striatum and substantia nigra in the rat. *Neuroscience*. 2002; 109(1): 89-99.
21. Naidu PS, Singh A, Kaur P, Sandhir R, Kulkarni SK. Possible mechanism of action in melatonin attenuation of haloperidol-induced orofacial dyskinesia. *Pharmacol Biochem Behav*. 2003; 74(3): 641-8.
22. Noh J.S., Ko H.W., Ryu B.R., Sohn S., Gwag B.J. Haloperidol-induced neuronal apoptosis: blockade by neurotrophins and IGFs. *Soc. Neurosci. Abst*. 1997; 24: 1046.
23. Parish CL, Finkelstein DI, Tripanichkul W, Satoskar AR, Drago J, Horne MK. The role of interleukin-1, interleukin-6, and glia in inducing growth of neuronal terminal arbors in mice. *J Neurosci*. 2002; 22(18): 8034-41.
24. Pena F, Tapia R. Seizures and neurodegeneration induced by 4-aminopyridine in rat hippocampus in vivo: role of glutamate- and GABA-mediated neurotransmission and of ion channels. *Neuroscience*. 2000; 101(3): 547-61
25. Polese D, de Serpis AA, Ambesi-Impiombato A, Muscettola G, de Bartolomeis A. Homer 1a gene expression modulation by antipsychotic drugs: involvement of the glutamate metabotropic system and effects of D-cycloserine. *Neuropsychopharmacology*. 2002; 27(6): 906-13.
26. Post A, Rucker M, Ohl F, Uhr M, Holsboer F, Almeida OF, Michaelidis TM. Mechanisms underlying the protective potential of alpha-tocopherol (vitamin E) against haloperidol-associated neurotoxicity. *Neuropsychopharmacology*. 2002; 26(3): 397-407.
27. Post A, Holsboer F, Behl C. Induction of NF-kappaB activity during haloperidol-induced oxidative toxicity in clonal hippocampal cells: suppression of NF-kappaB and neuroprotection by antioxidants. *J Neurosci*. 1998; 18(20): 8236-46.
28. Roberts RC, Force M, Kung L. Dopaminergic synapses in the matrix of the ventrolateral striatum after chronic haloperidol treatment. *Synapse*. 2002; 45(2): 78-85.
29. Roussinov KS, Yonkov D. Comparative studies on the effect of lithium and haloperidol on learning and memory *Acta Physiol Pharmacol Bulg* 1975; 3-4: 51-7.
30. Terry AV, Hill WD, Parikh V, Waller JL, Evans DR, Mahadik SP. Differential effects of haloperidol, risperidone, and clozapine exposure on cholinergic markers and spatial learning performance in rats. *Neuropsychopharmacology* 2003; 28(2): 300-9.
31. Unal B, Özbek ME, Aydın D, Aydın N, Bulucu Z, Vuraler Ö, Odaci E, Sahin B, Kaplan S (2004) The effect of haloperidol on the numerical density of neurons and nuclear height in the rat hippocampus (A stereological and histopathological study). *Neuroscience Research Communications*, 2004; 34: 1-9.
32. Uranova NA, Orlovskaya DD, Apel K, Klintsova AJ, Haselhorst U, Schenk H. Morphometric study of synaptic patterns in the rat caudate nucleus and hippocampus under haloperidol treatment. *Synapse*. 1991; 7(4): 253-9.
33. Vilner BJ, Bowen WD. Sigma receptor-active neuroleptics are cytotoxic to C6 glioma cells in culture. *Eur J Pharmacol*. 1993; 244(2): 199-201.
34. Vincent SL, McSparren J, Wang RY, Benes FM. Evidence for ultrastructural changes in cortical axodendritic synapses following long-term treatment with haloperidol or clozapine. *Neuropsychopharmacology*. 1991; 5(3): 147-55.
35. Wakade CG, Mahadik SP, Waller JL, Chiu FC. Atypical neuroleptic stimulate neurogenesis in adult rat brain *J Neurosci Res* 2002; 69(1): 72-9.
36. Walsh TJ, Emerich DF. The hippocampus as a common target of neurotoxic agents. *Toxicology*. 1988; 49(1): 137-40.
37. Welch JJ, Kim HS, Liebman J. Amphetamine-induced increases in dopaminergic single cell firing rate after haloperidol pretreatment. Correlation with extrapyramidal side effects. *Neuropharmacology*. 1980; 19(4): 371-7.